第12回京都乳癌コンセンサス会議
ミニレクチャー「特殊型乳癌の病理」

第3回

Apocrine carcinoma
アポクリン癌

三上芳喜
京都大学医学部附属病院病理診断部

特殊型乳癌

乳癌取扱い規約第16版
（2008年）

- 粘液癌
- 髄様癌
- 浸潤性小葉癌
- 腺様嚢胞癌
- 扁平上皮癌
- 紡錘細胞癌
- アポクリン癌
- 骨･軟骨化生を伴う癌
- 管状癌
- 分泌癌（若年性癌）
- 浸潤性微小乳頭癌
- 基質産生癌
- その他

乳癌の各組織型の頻度

In situ carcinoma	**15-30%**
非浸潤性乳管癌	80%
非浸潤性小葉癌	20%
Invasive carcinoma	**70-85%**
乳管癌（非特殊型）	79%
小葉癌	10%
管状癌 / 篩状癌	6%
粘液癌	2%
髄様癌	2%
乳頭癌	1%
化生癌	< 1%

Robbins and Cotran Pathologic Basis of Disease, Professional Edition, 8th Edition

アポクリン癌
Apocrine carcinoma

- 稀（乳がんの<u>1%以下</u>～4%）
  - “focal apocrine features” ⇒ 63% (Miller et al.)
- 全て、あるいは殆どの腫瘍細胞がアポクリン上皮の特徴を有するもの
- 豊富な好酸性顆粒状（PAS陽性）細胞質を有する大型の腫瘍細胞から構成

アポクリン癌
Apocrine carcinoma

- 臨床像
  - 特徴的な臨床像はない
  - 発生年齢:19～86歳
  - 閉経後に好発？
  - 脳転移をきたしやすい？

アポクリン癌
Apocrine carcinoma

- 組織像
  - 通常の浸潤性乳管癌と同様のパターン
  - Grade-I～grade-III
  - リンパ管侵襲が多い傾向
    ⇒炎症性パターンを示す再発

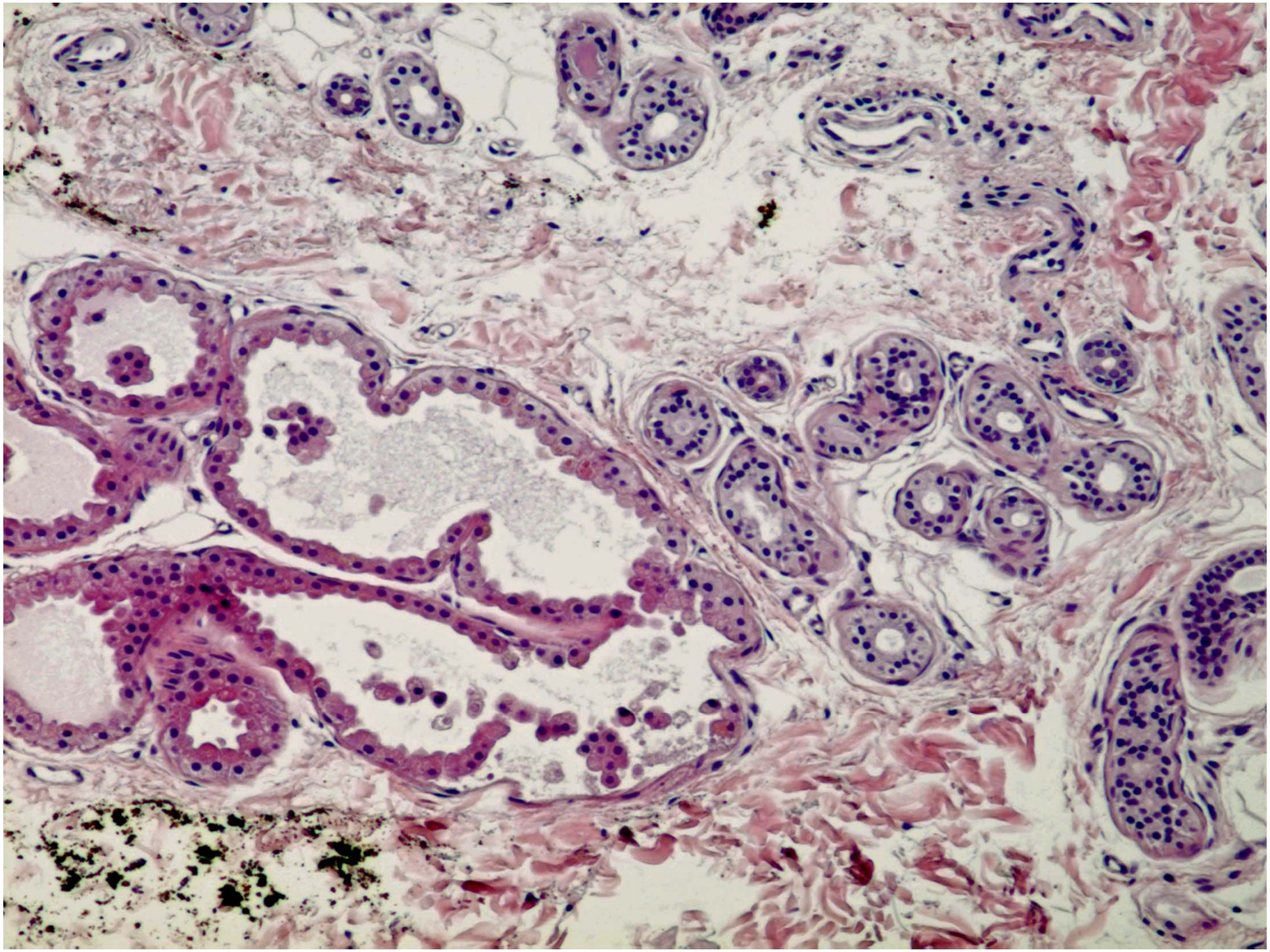

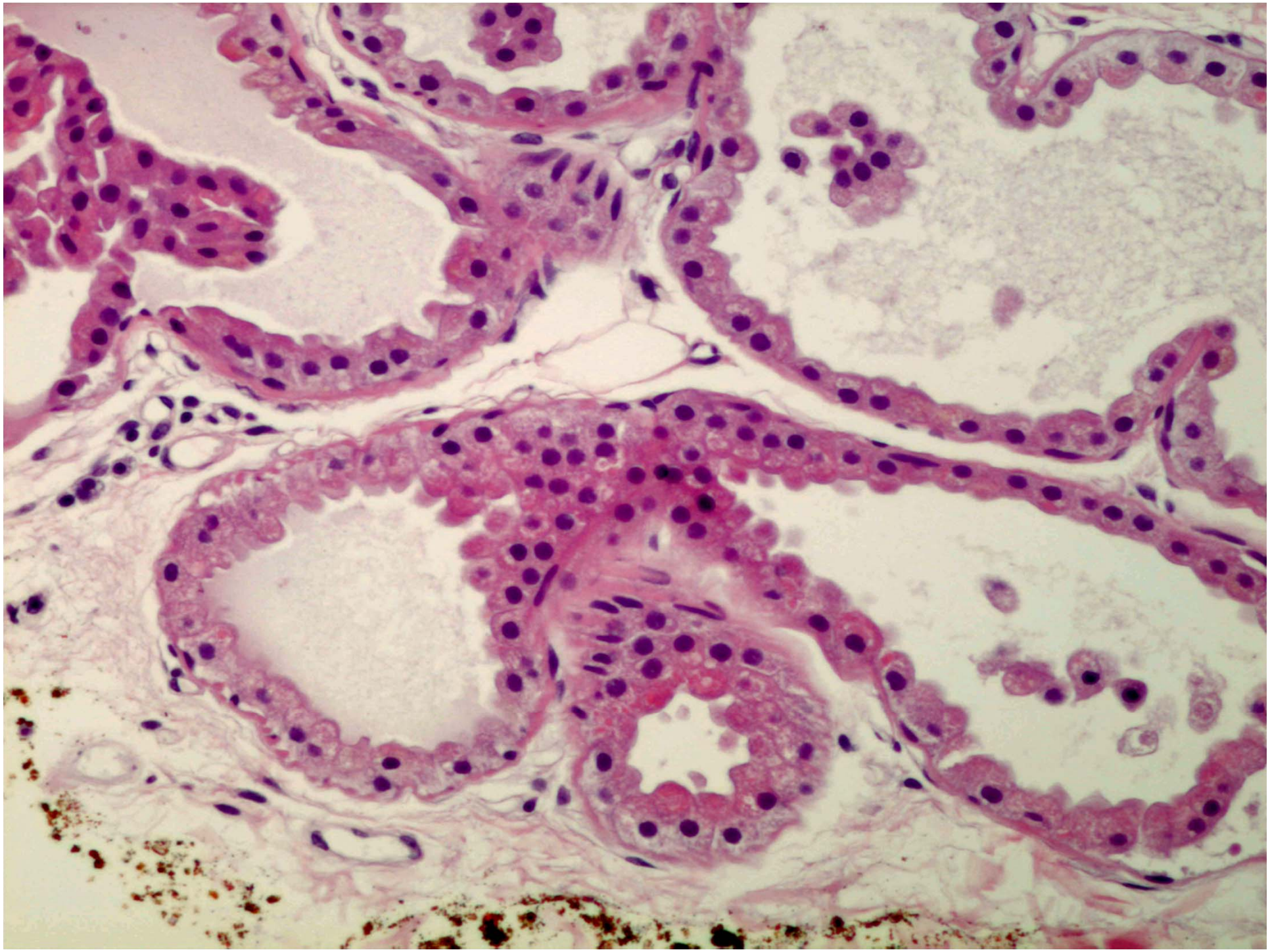

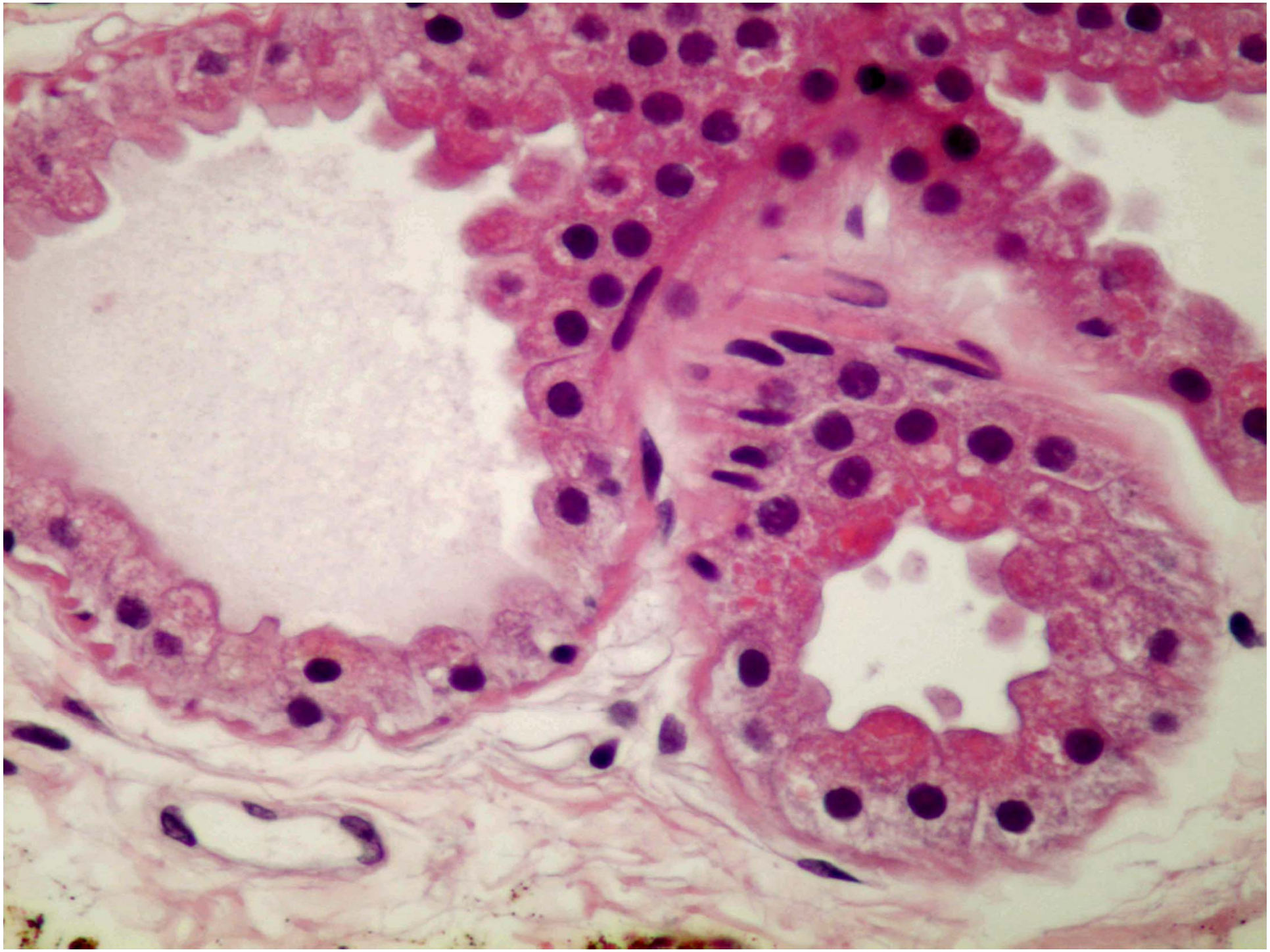

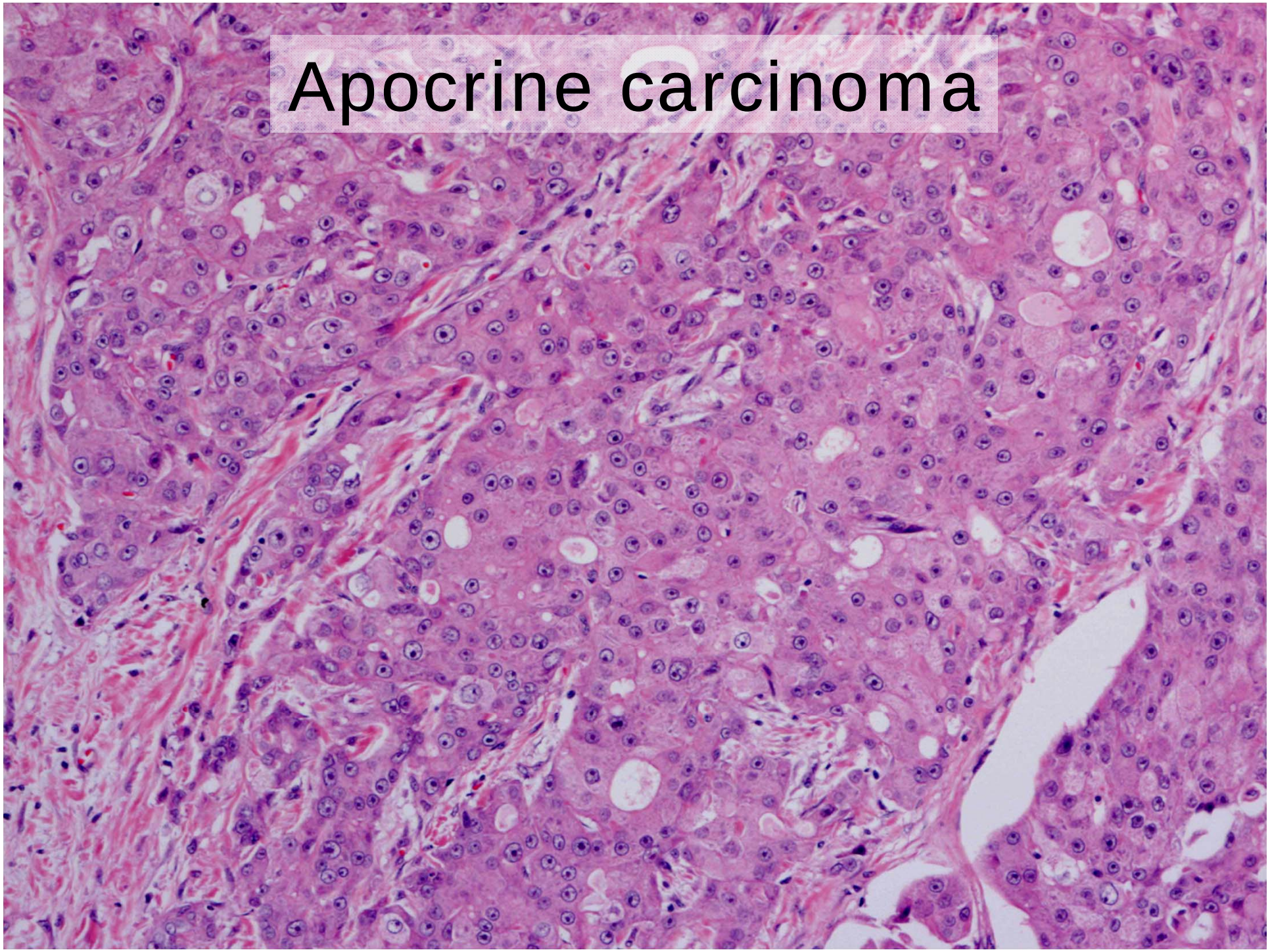
Apocrine carcinoma

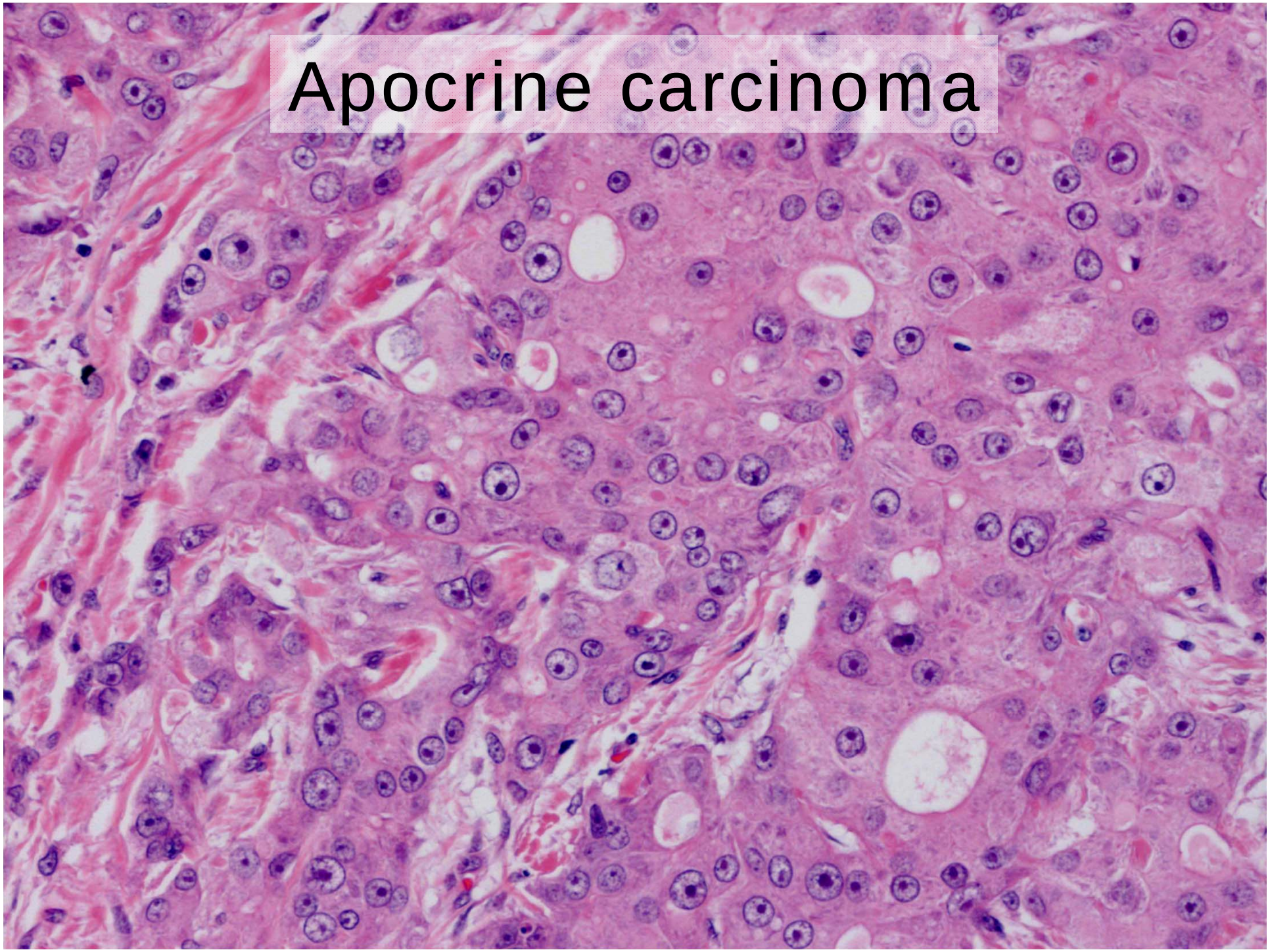
Apocrine carcinoma

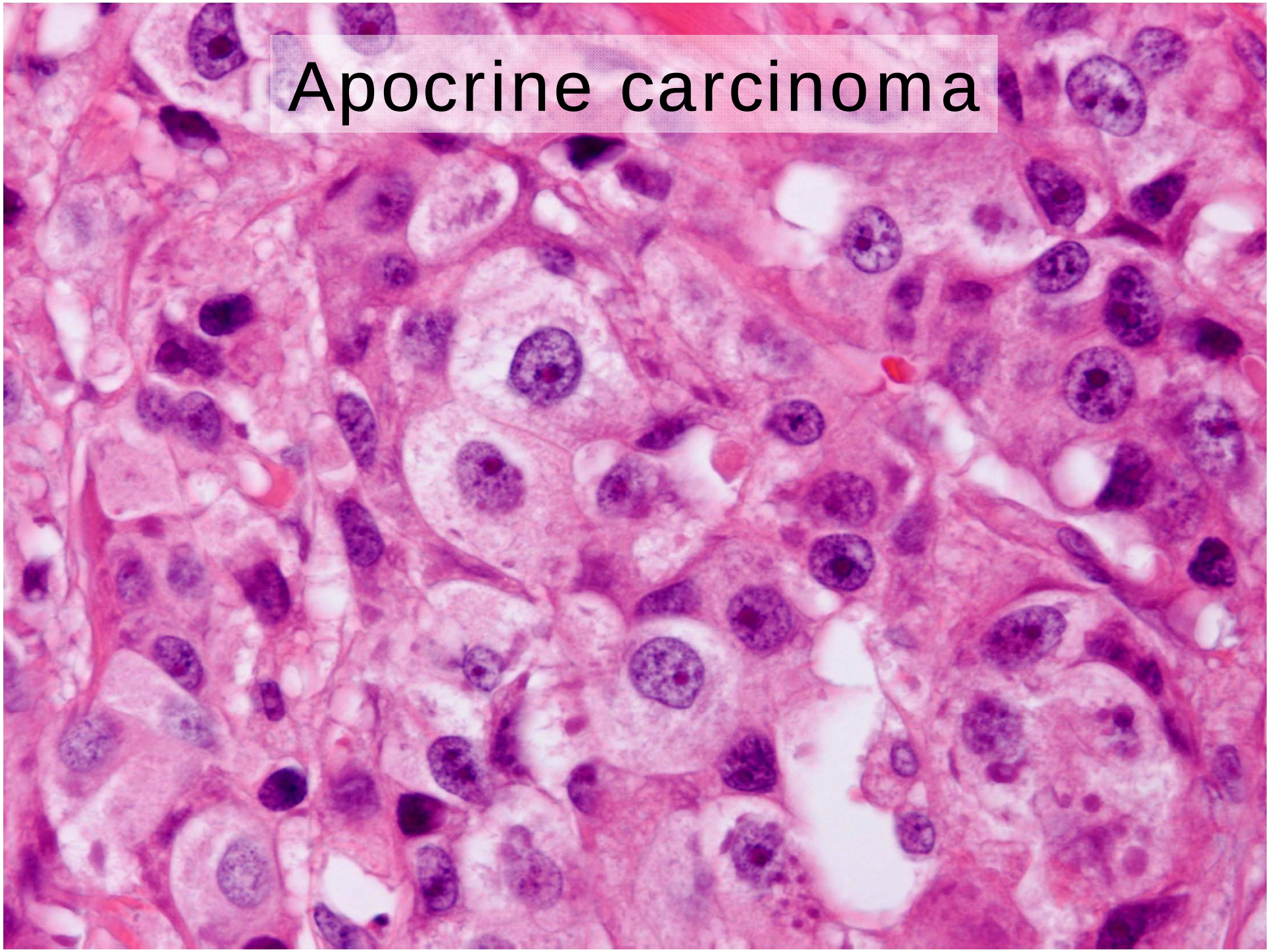
Apocrine carcinoma

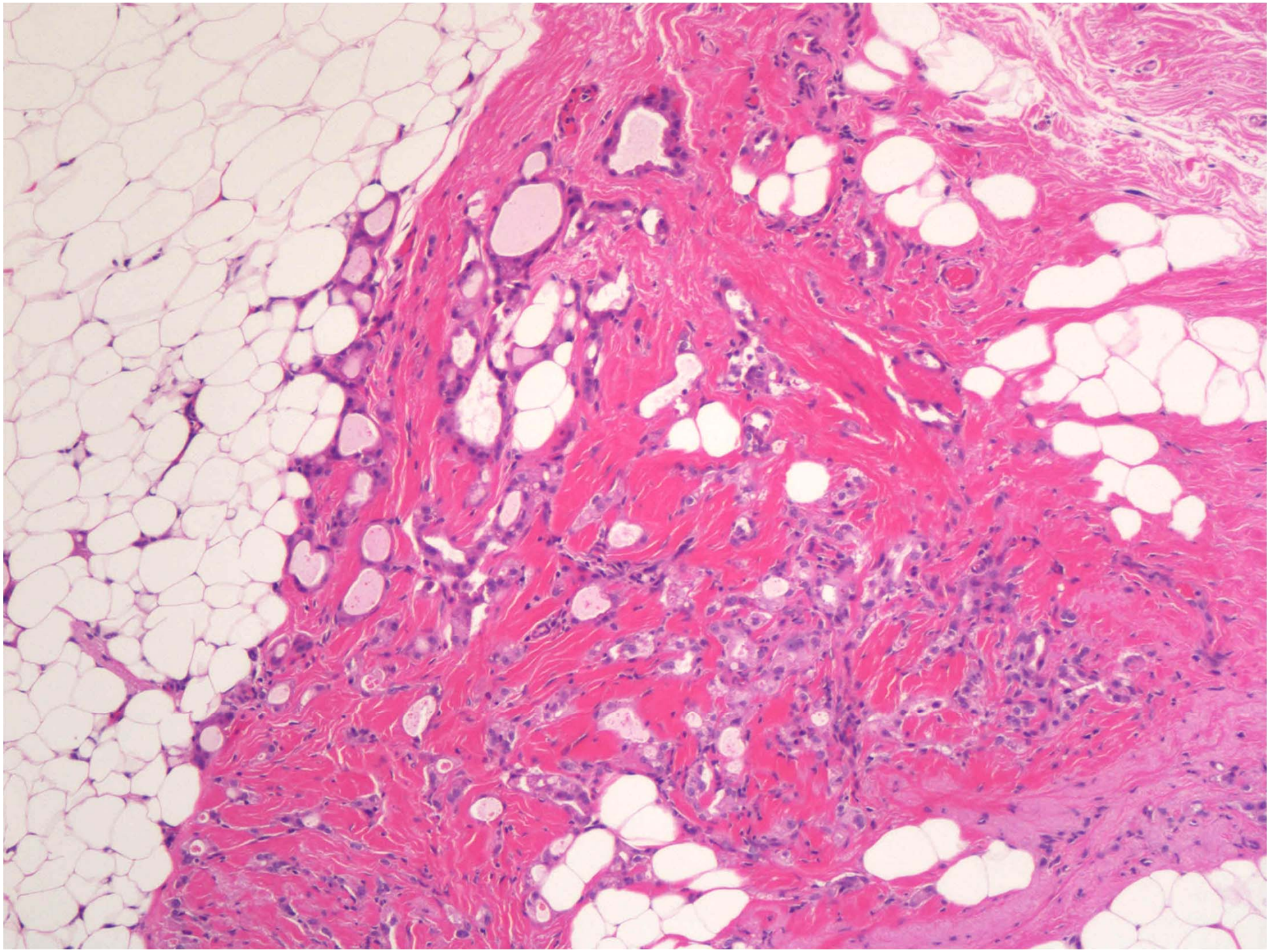

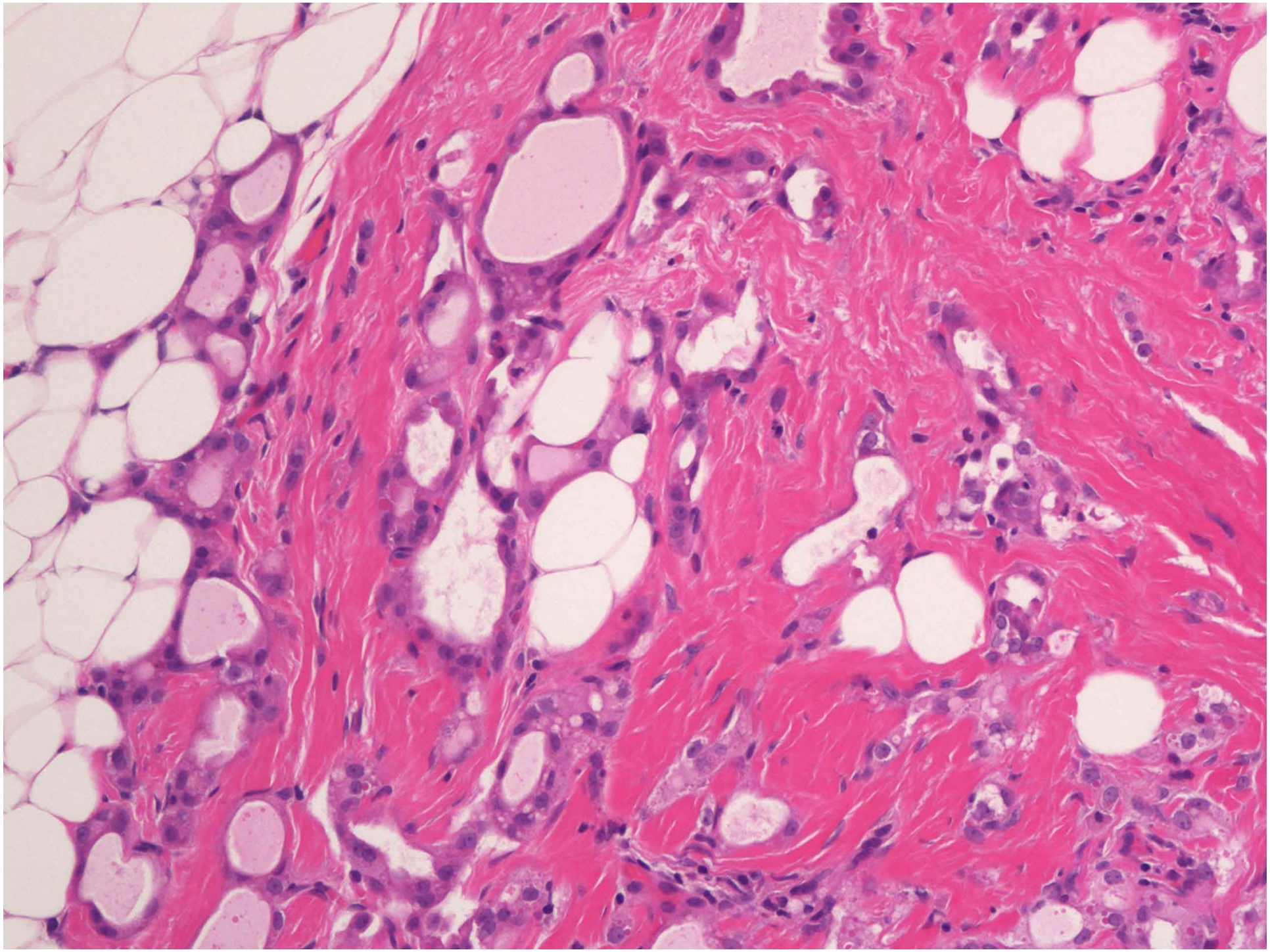

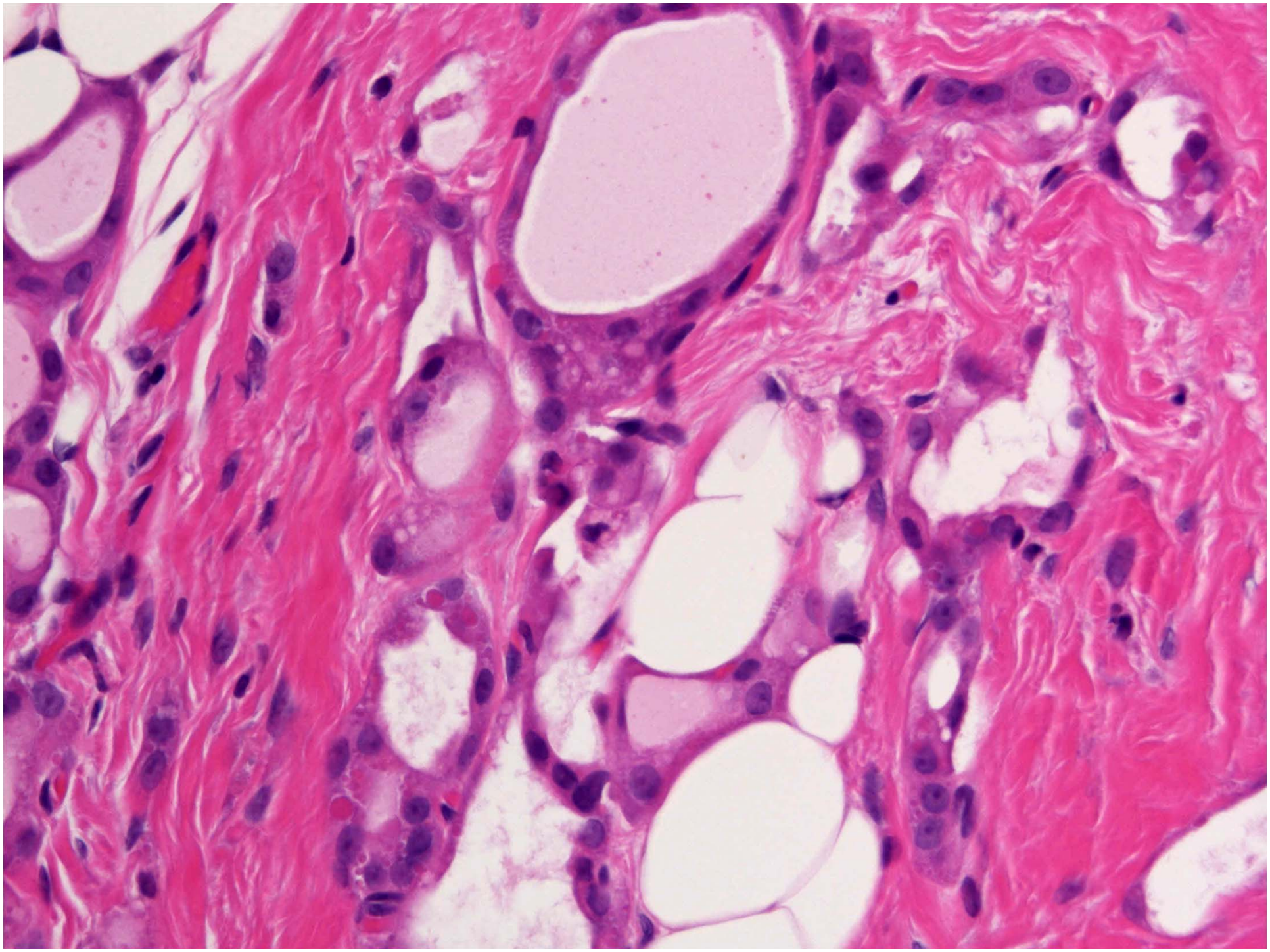

アポクリン癌
Apocrine carcinoma

- Ductal carcinoma
- Lobular carcinoma (histiocytoid variant)

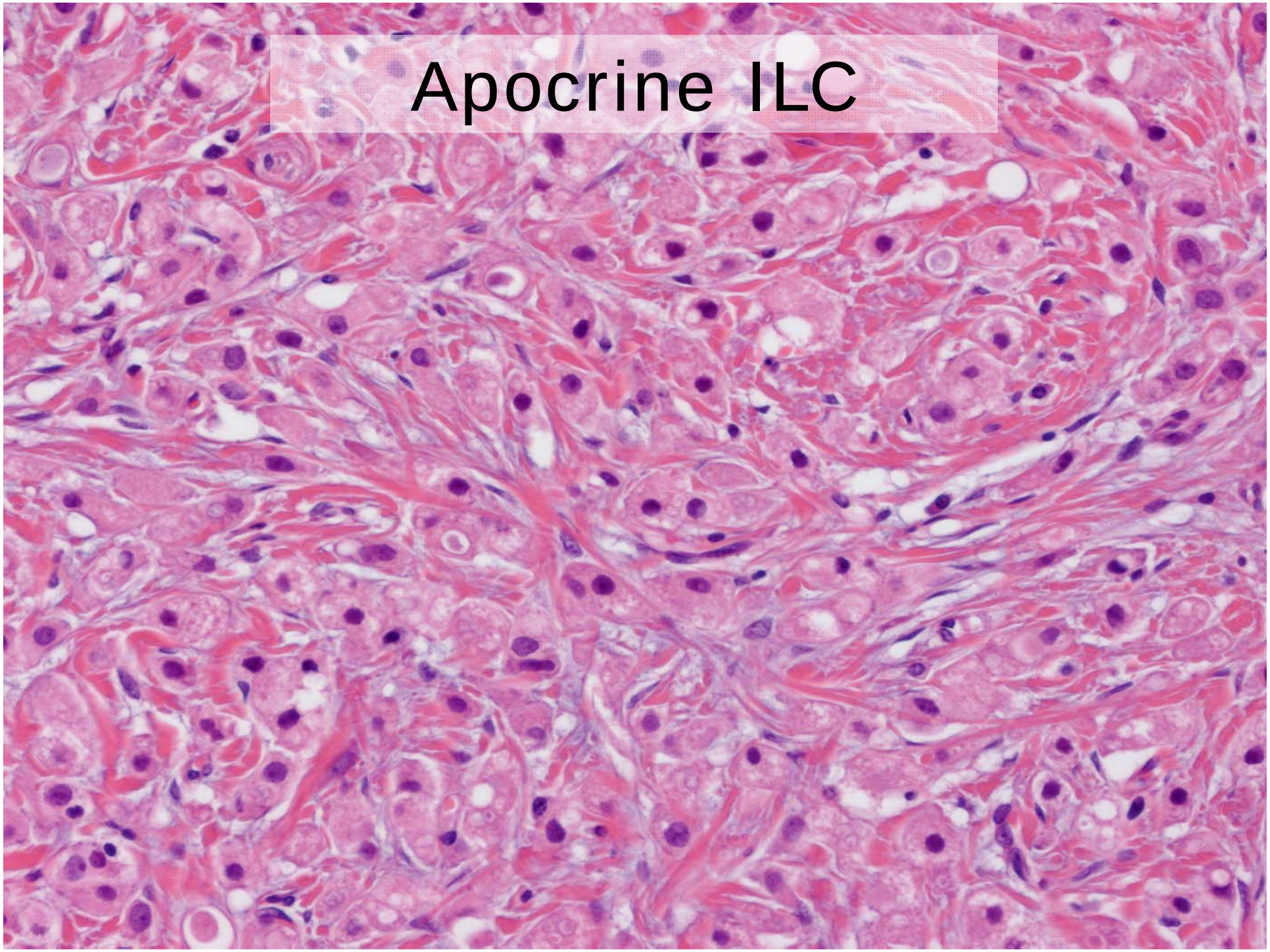
Apocrine ILC

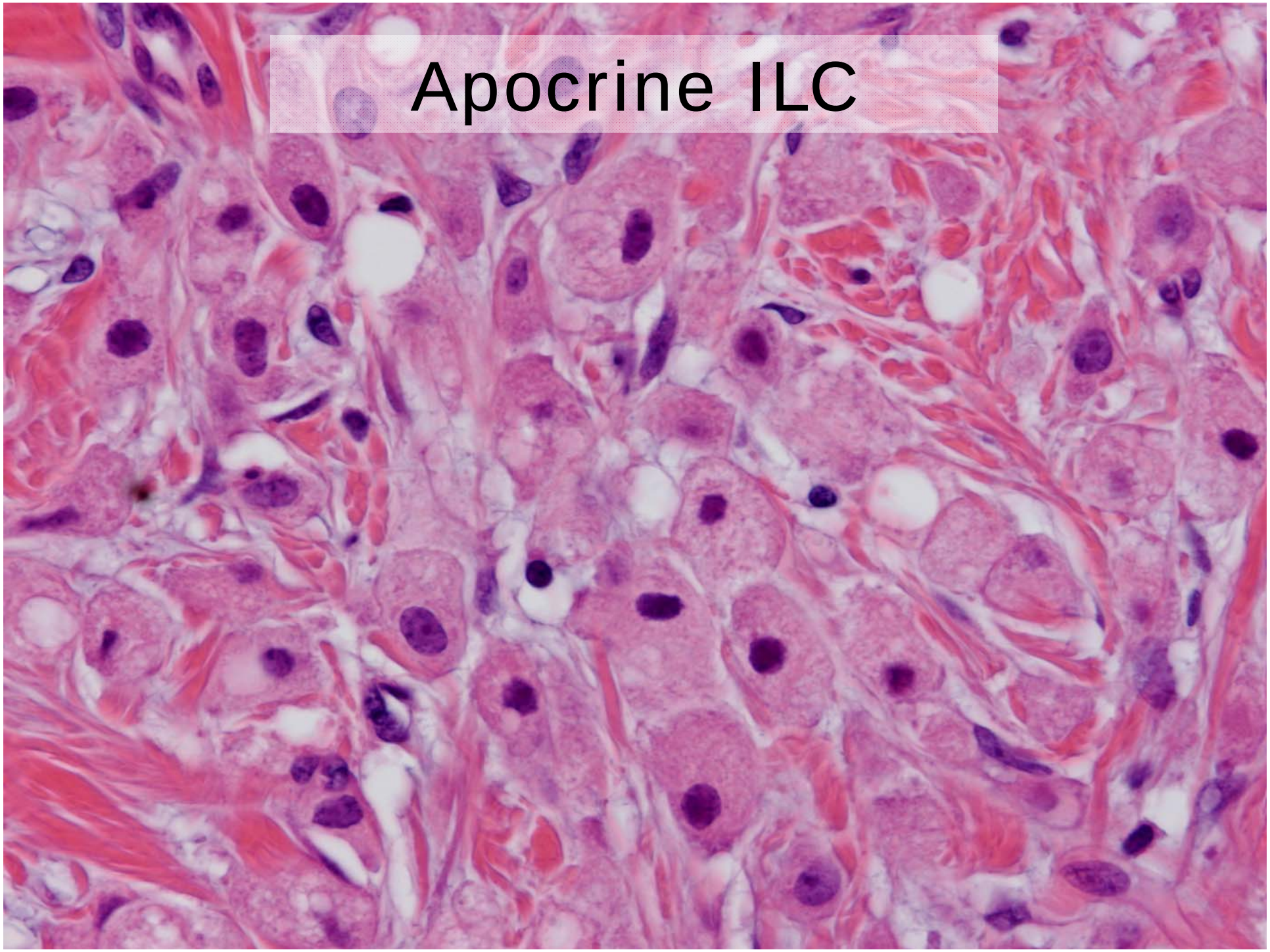
Apocrine ILC

アポクリン癌
Apocrine carcinoma

- 鑑別診断

Apocrine adenosis

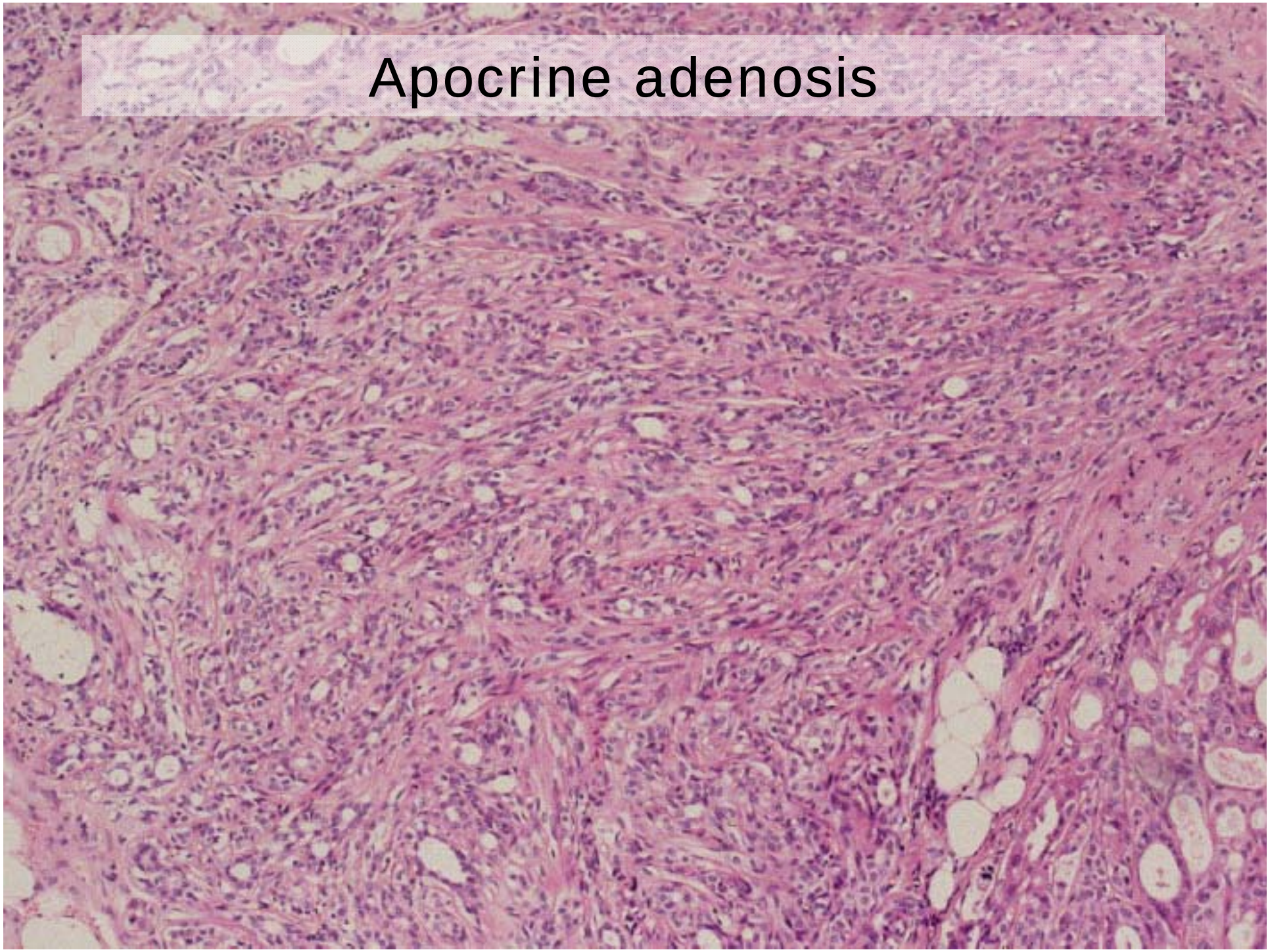

Apocrine adenosis

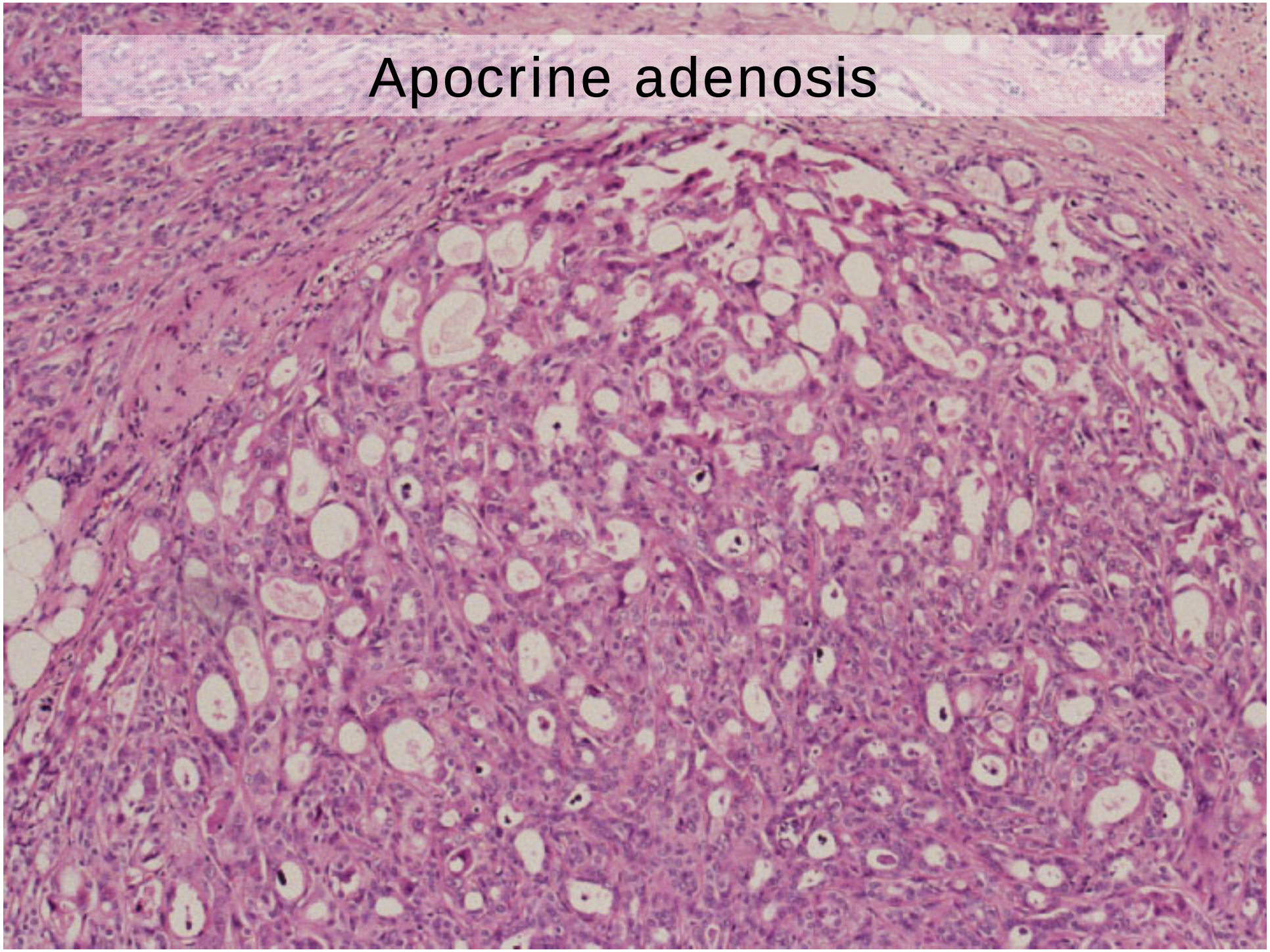

Apocrine adenosis

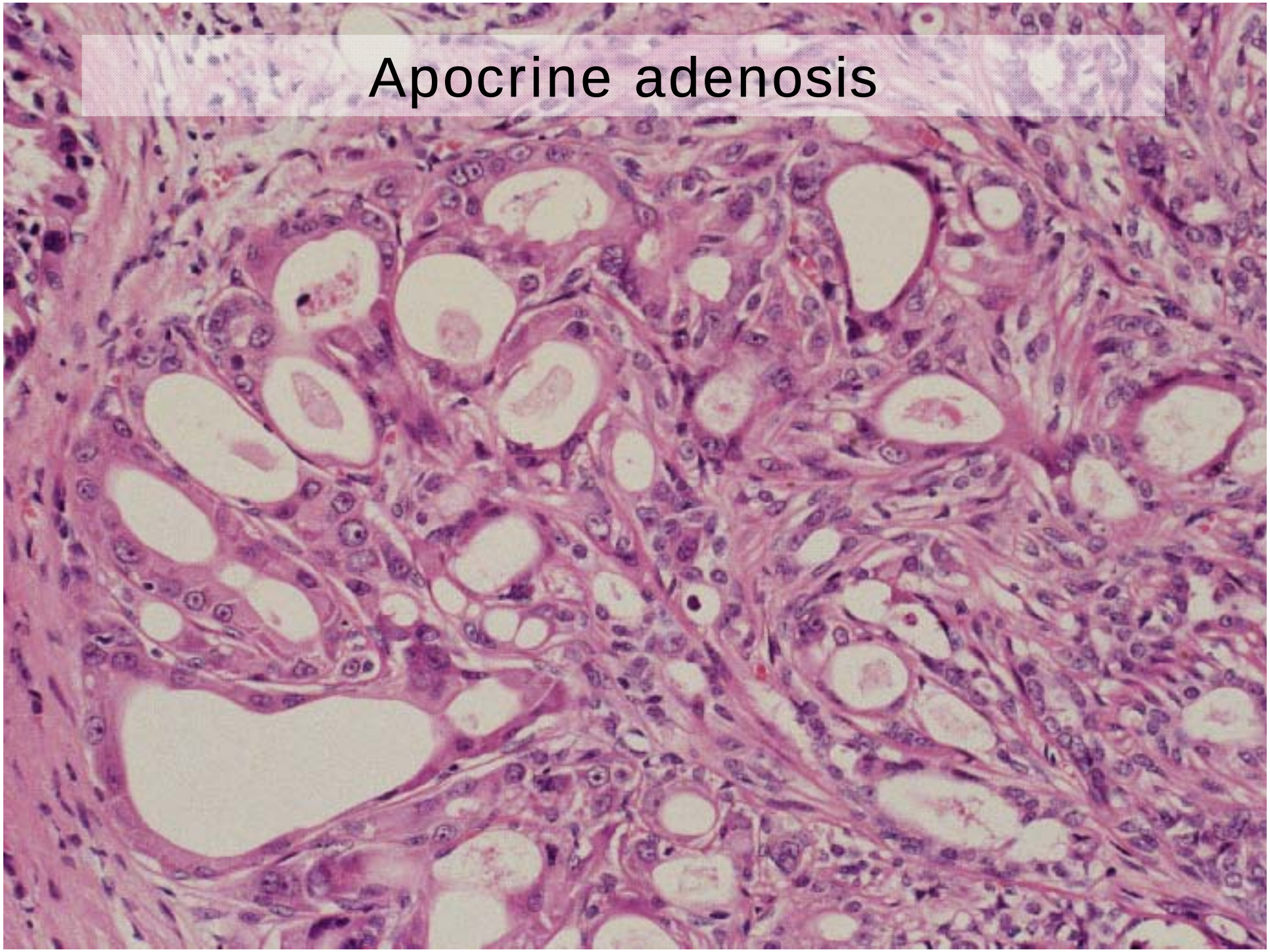

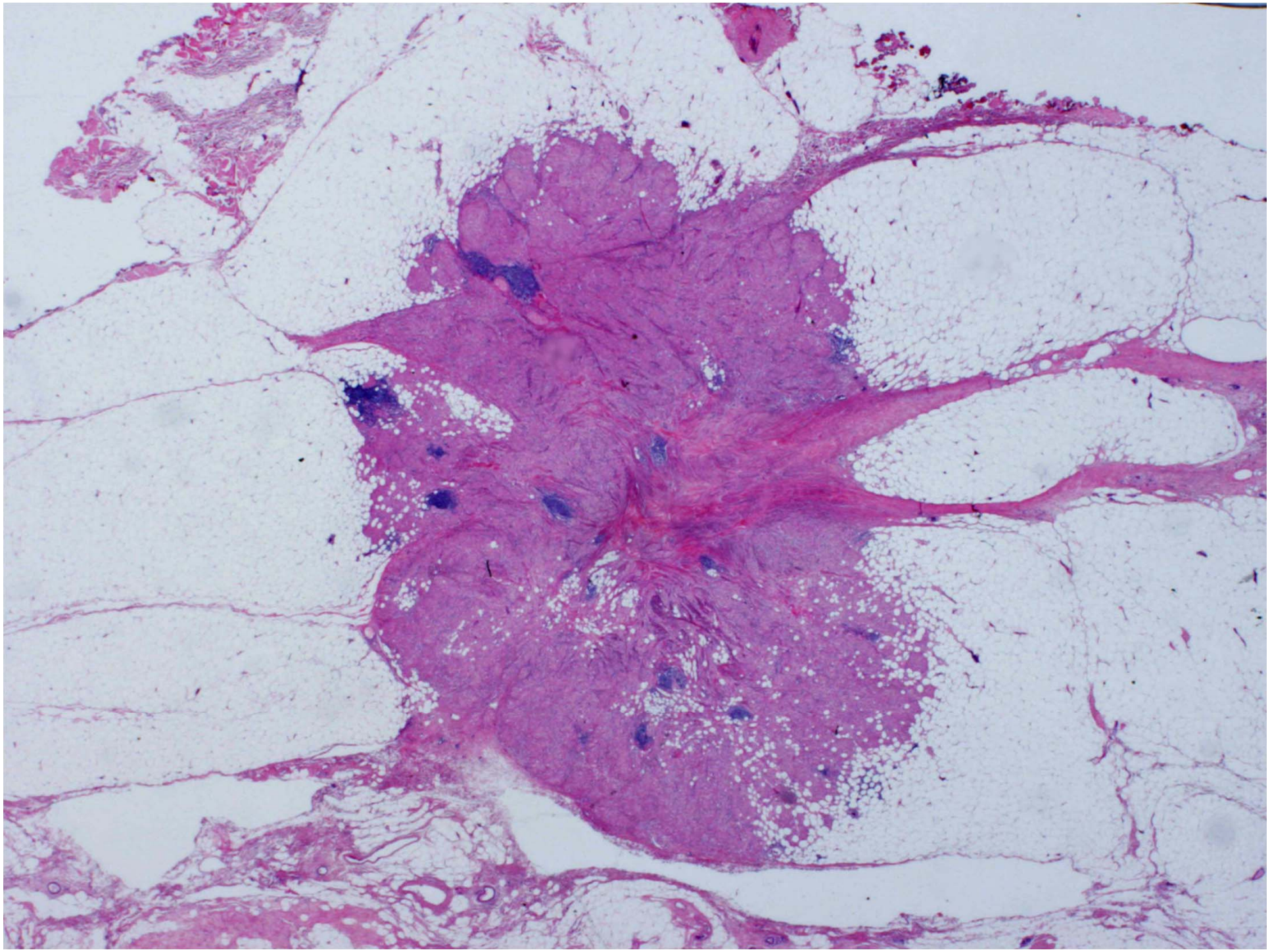

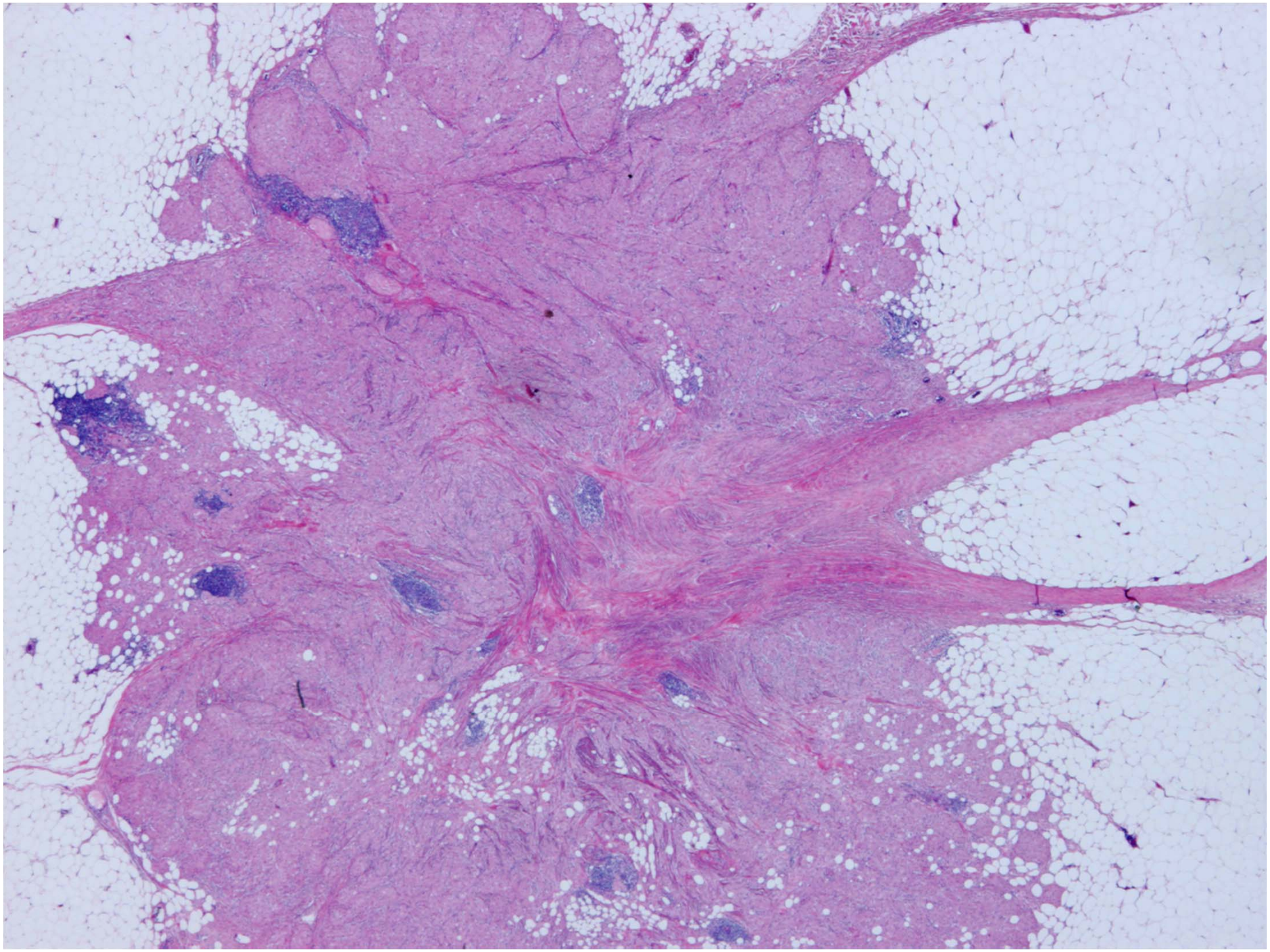

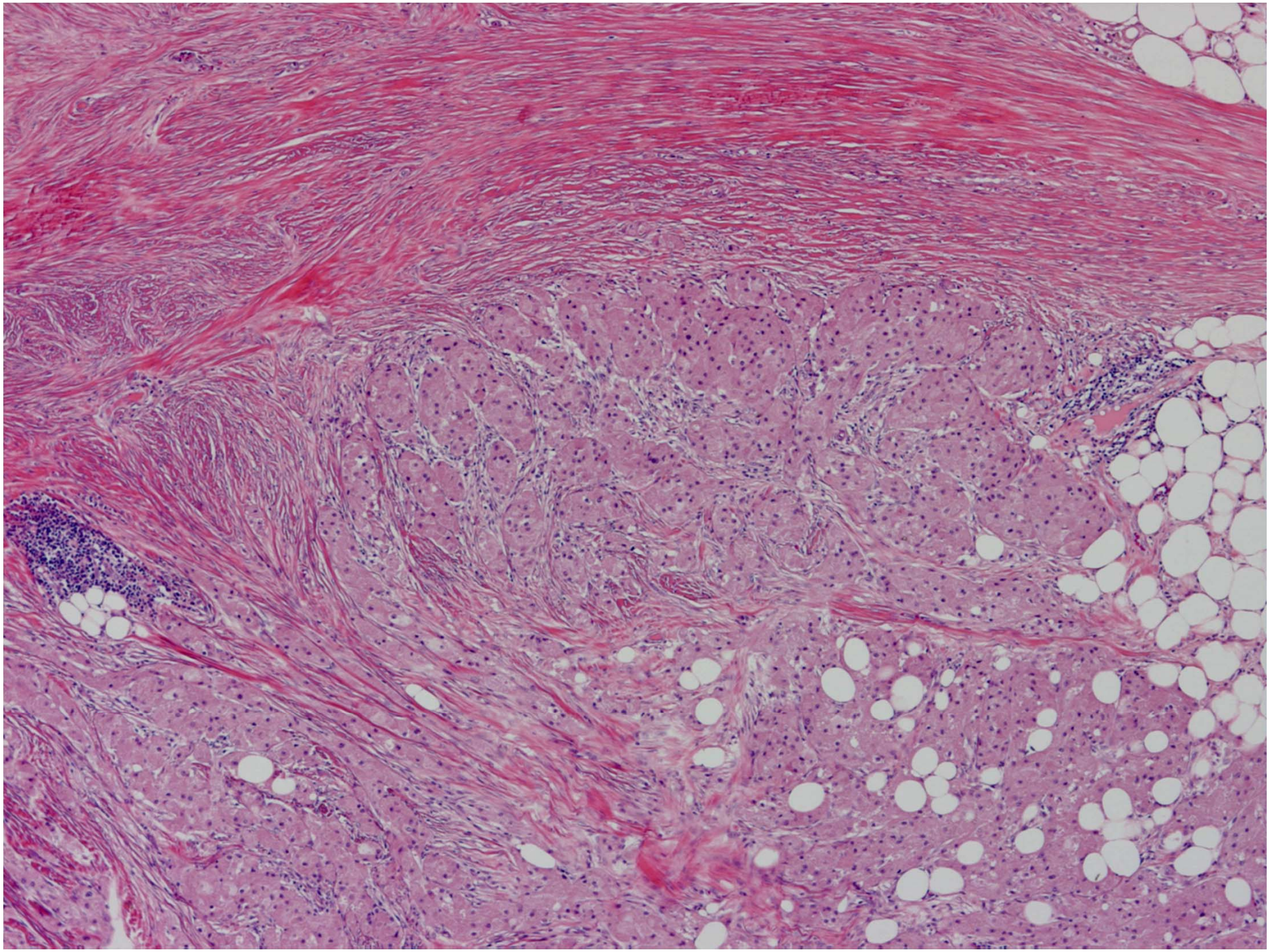

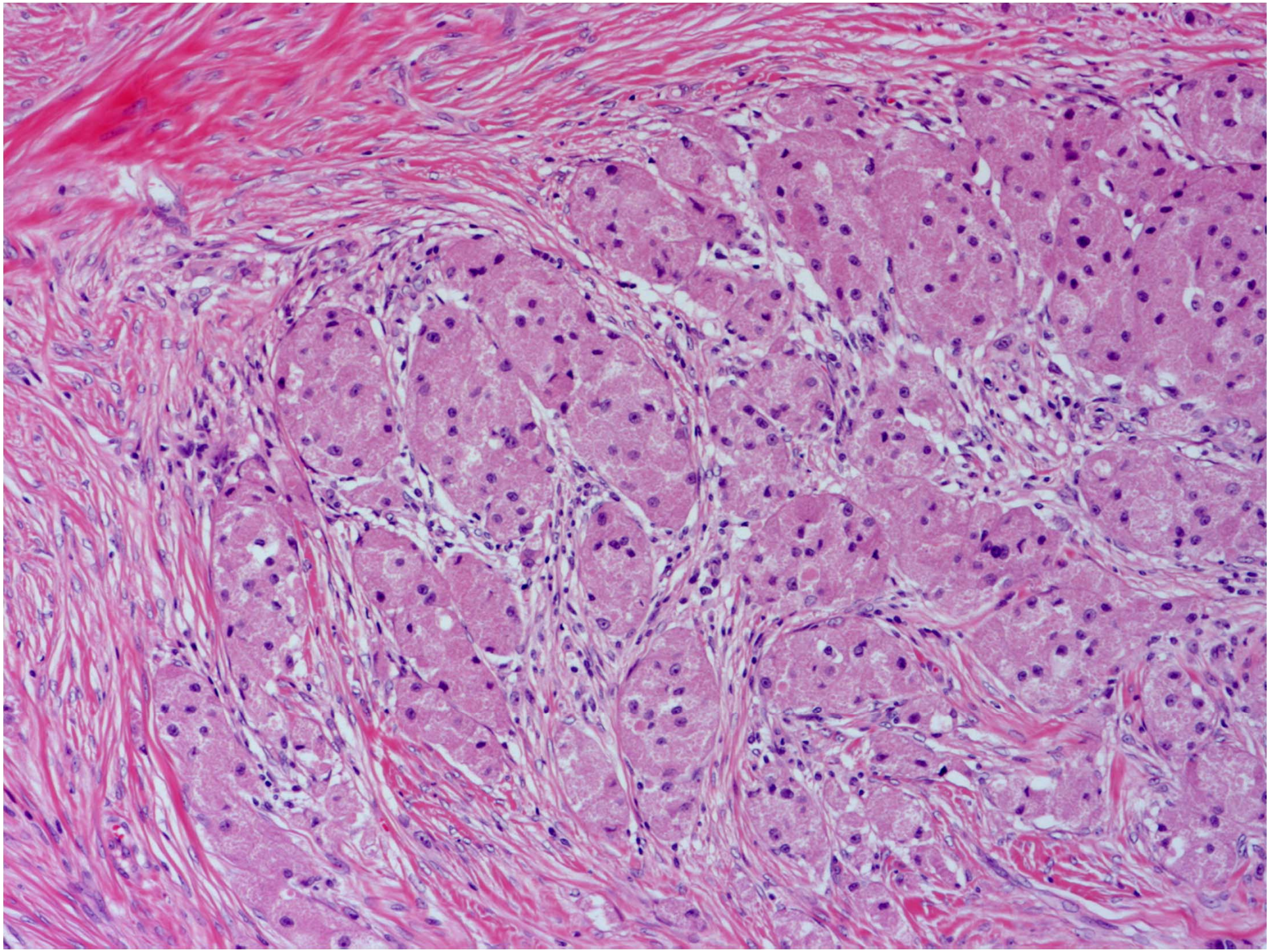

顆粒細胞腫 Granular cell tumor

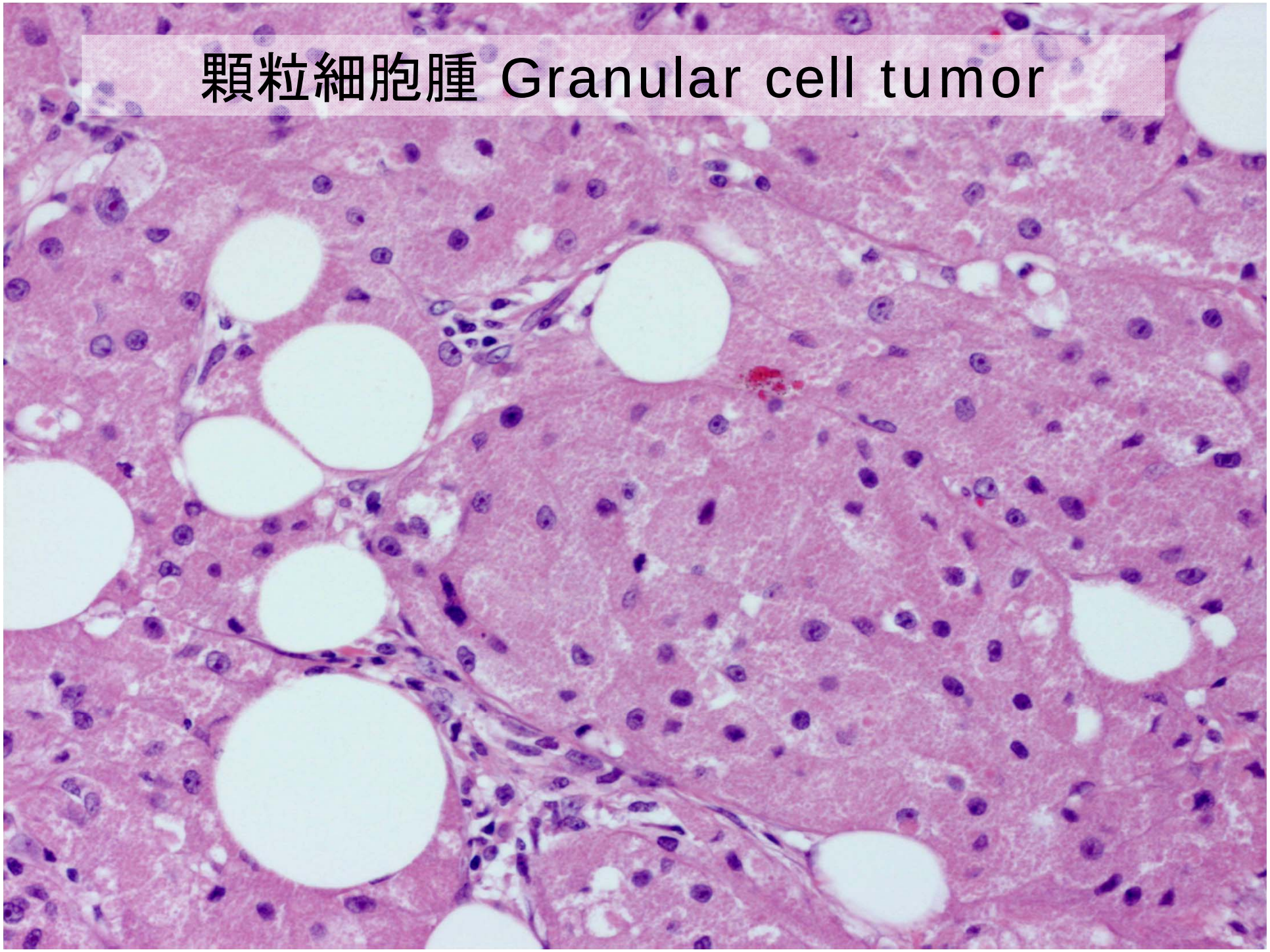

アポクリン癌
Apocrine carcinoma

- 治療と予後
  - 生存率は非アポクリン癌と同等 (Frable et al., d'Amore et al., Abati et tal.)
  - 予後因子：①grade、②腫瘍径、③リンパ節転移の有無
  - 表現型（ER/PR/HER2）（±Ki-67標識率）を勘案の上、治療方針決定

アポクリン型非浸潤性乳管癌
Apocrine DCIS

- アポクリン形態を示す細胞形態
- 通常のDCISでみられる構築パターン
  - 乳頭状、微小乳頭状、篩状、充実性、面疱型

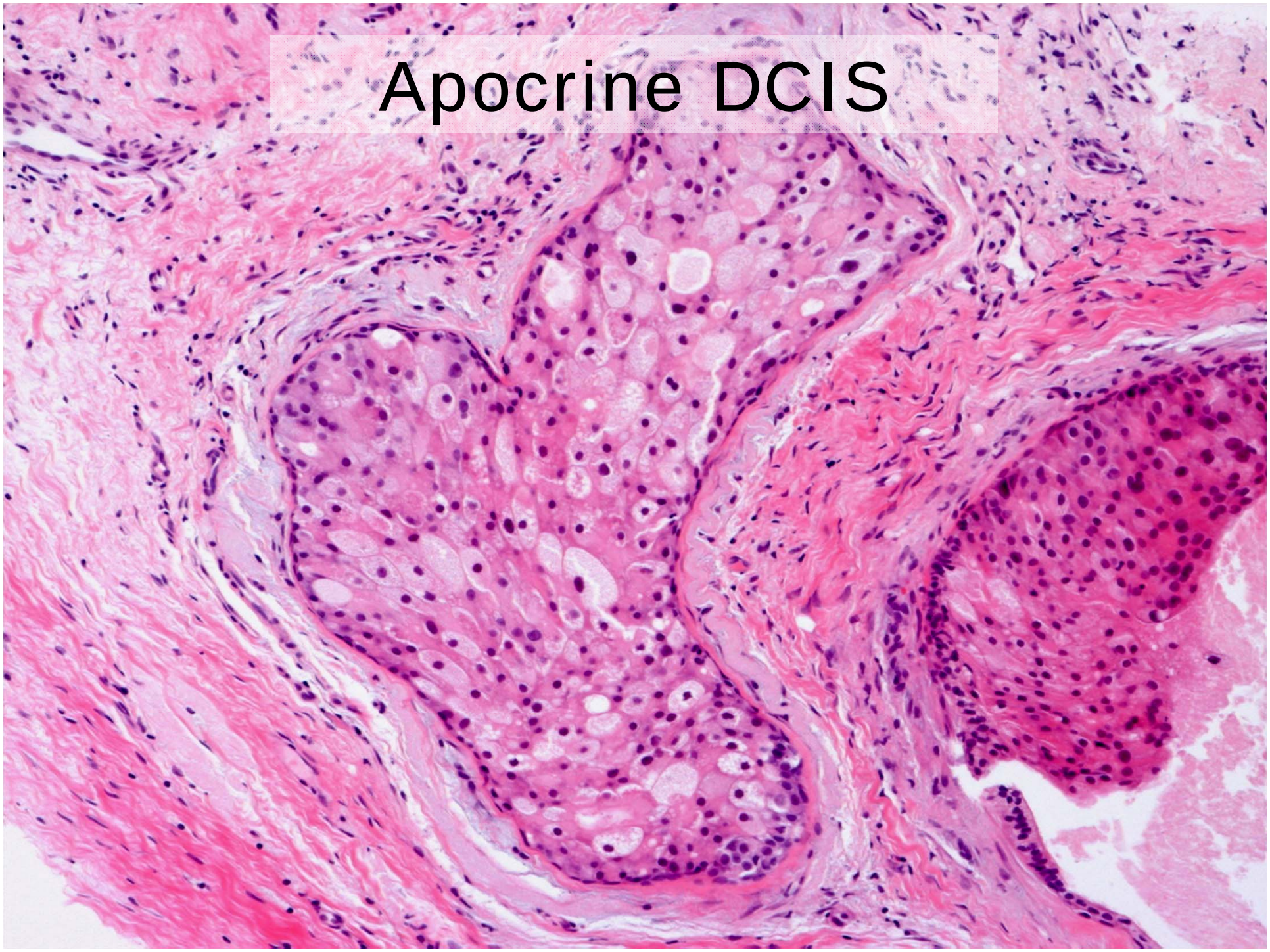
Apocrine DCIS

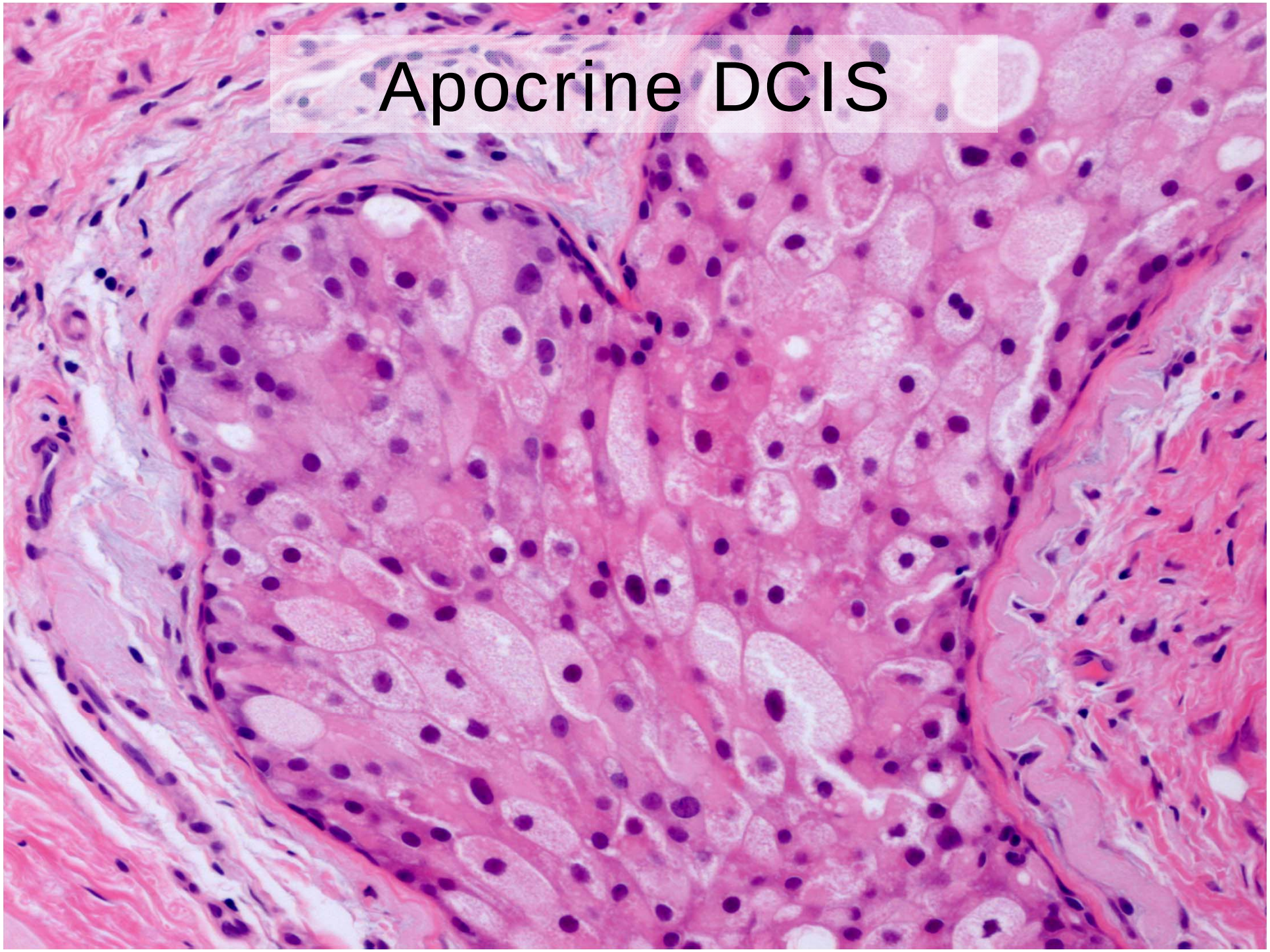
Apocrine DCIS

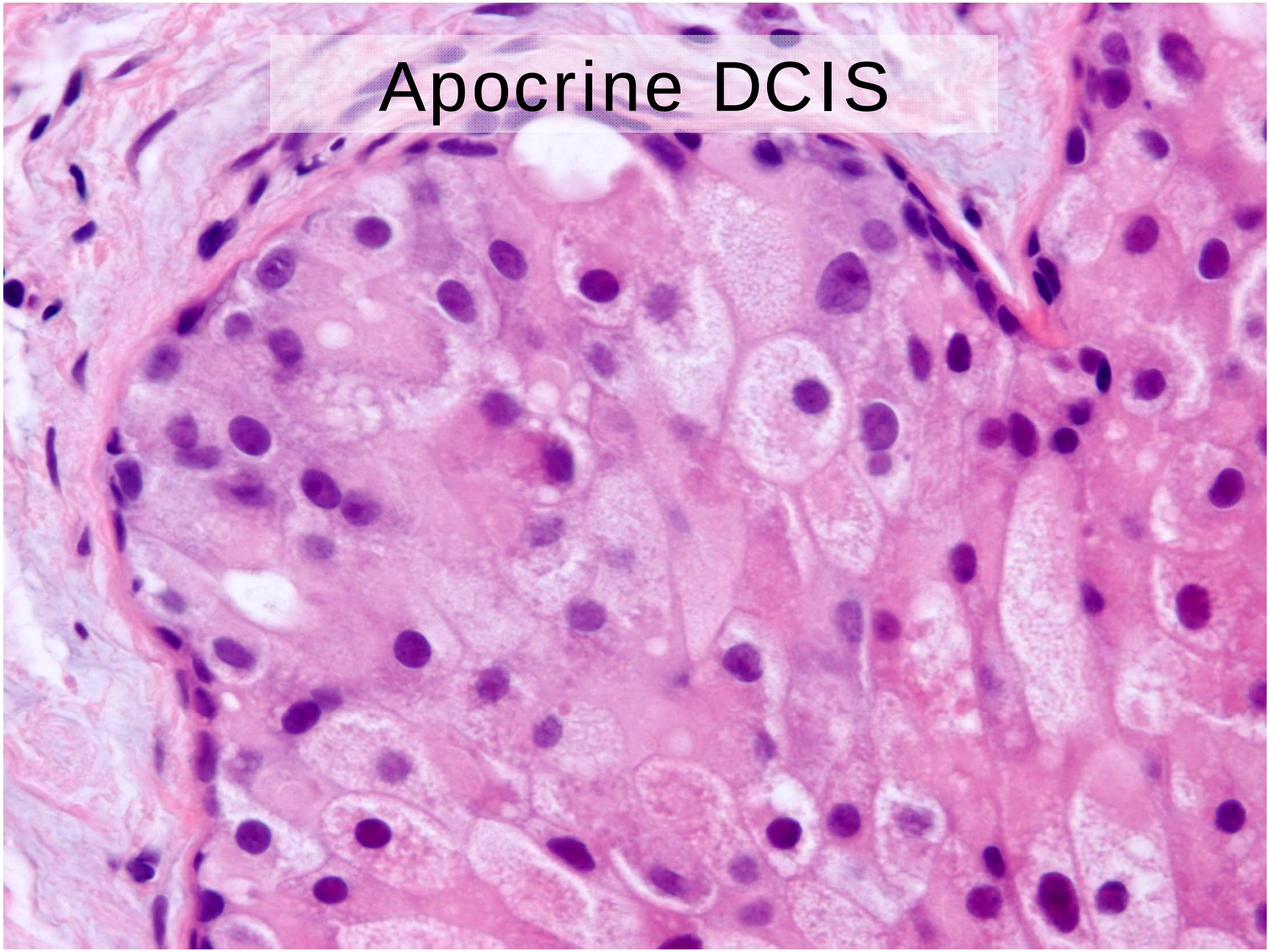
Apocrine DCIS

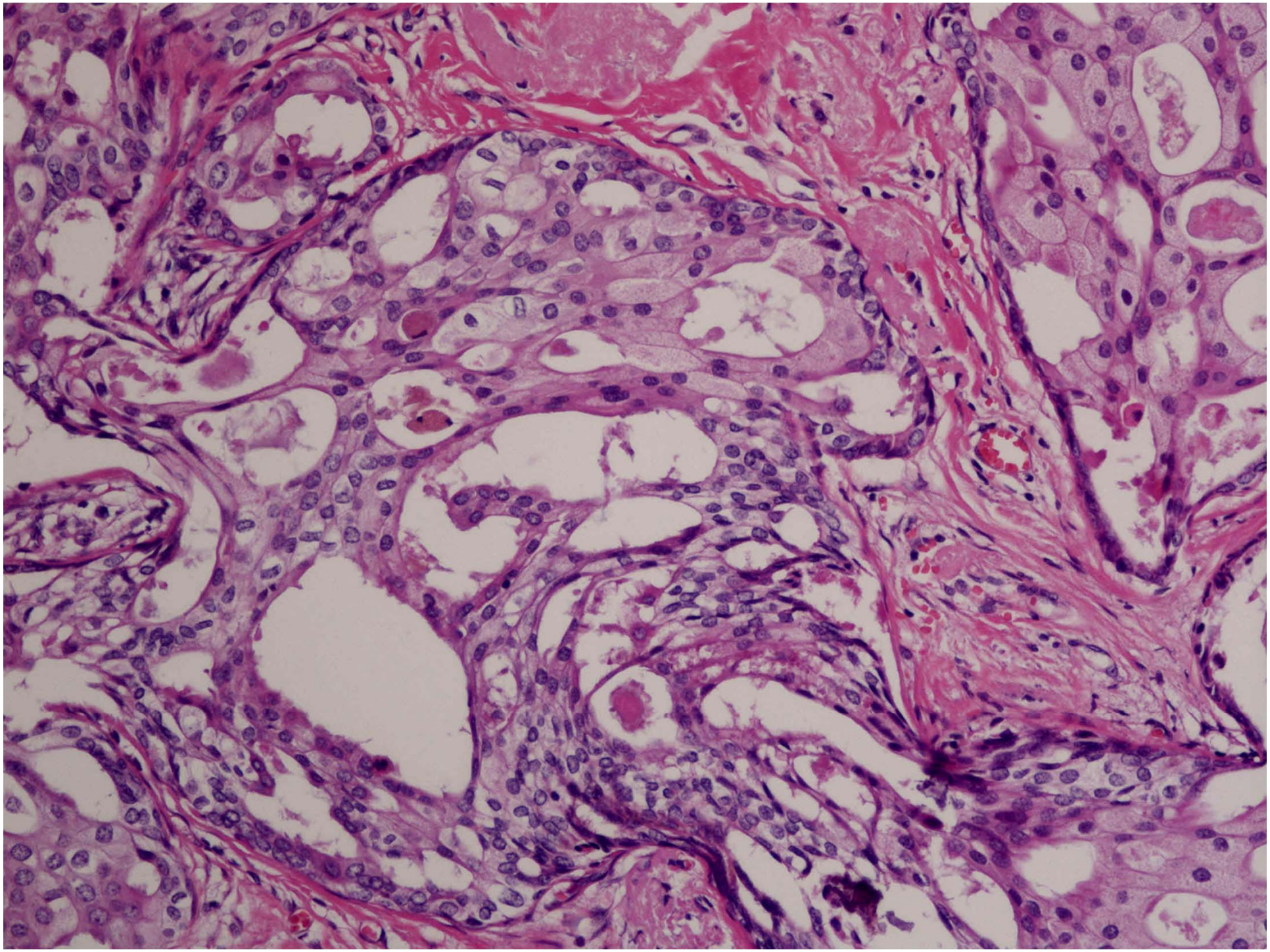

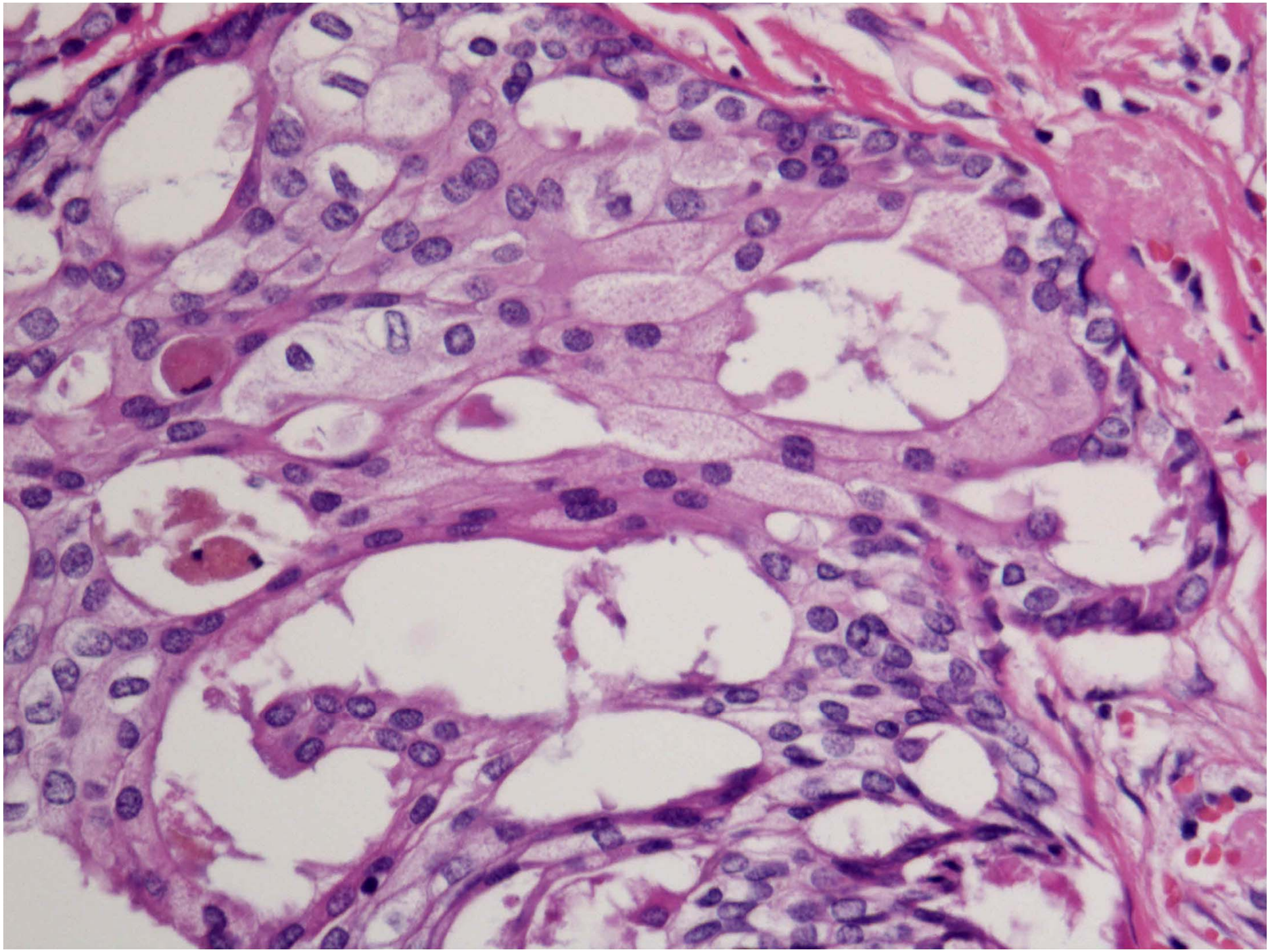

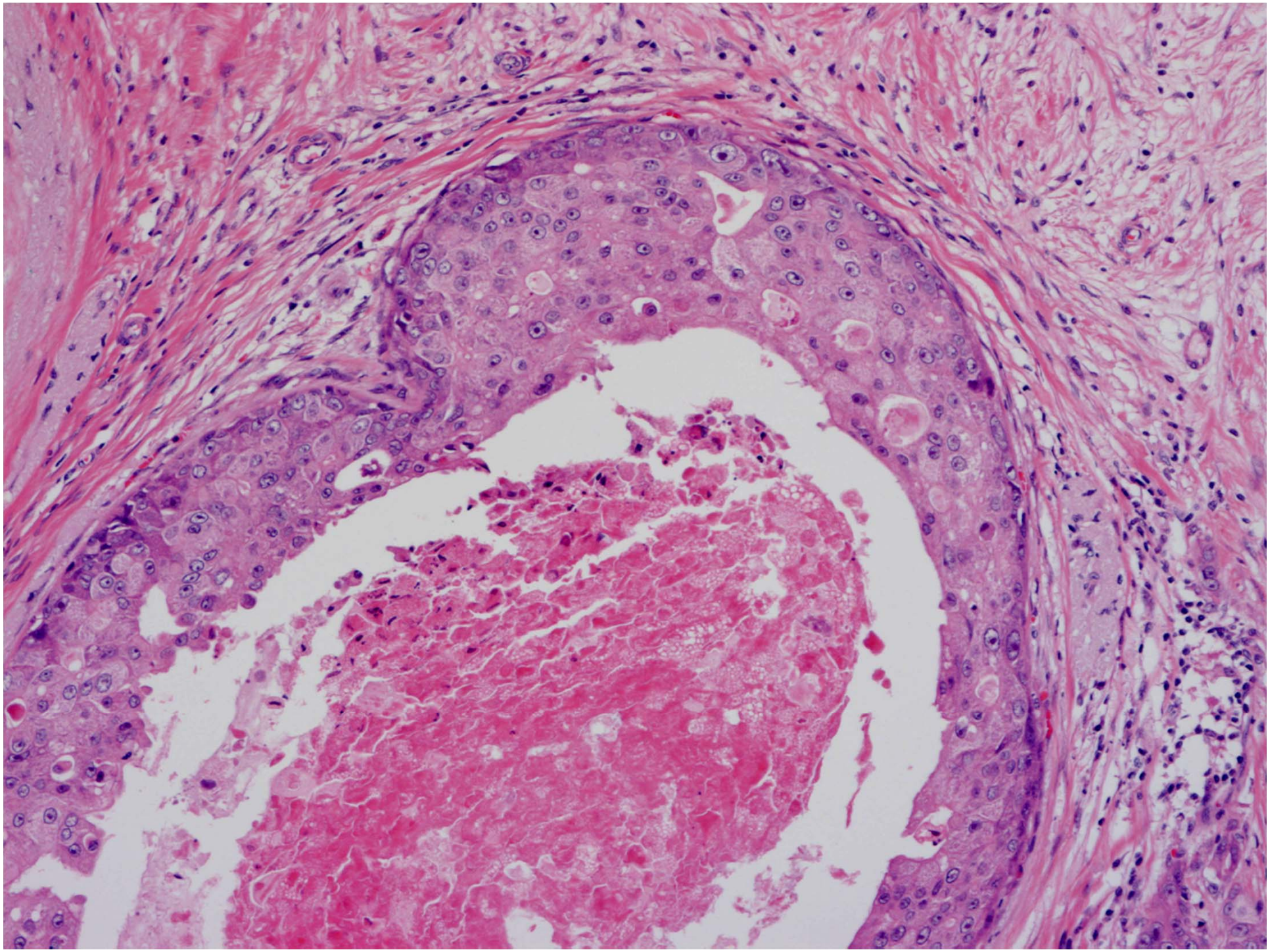

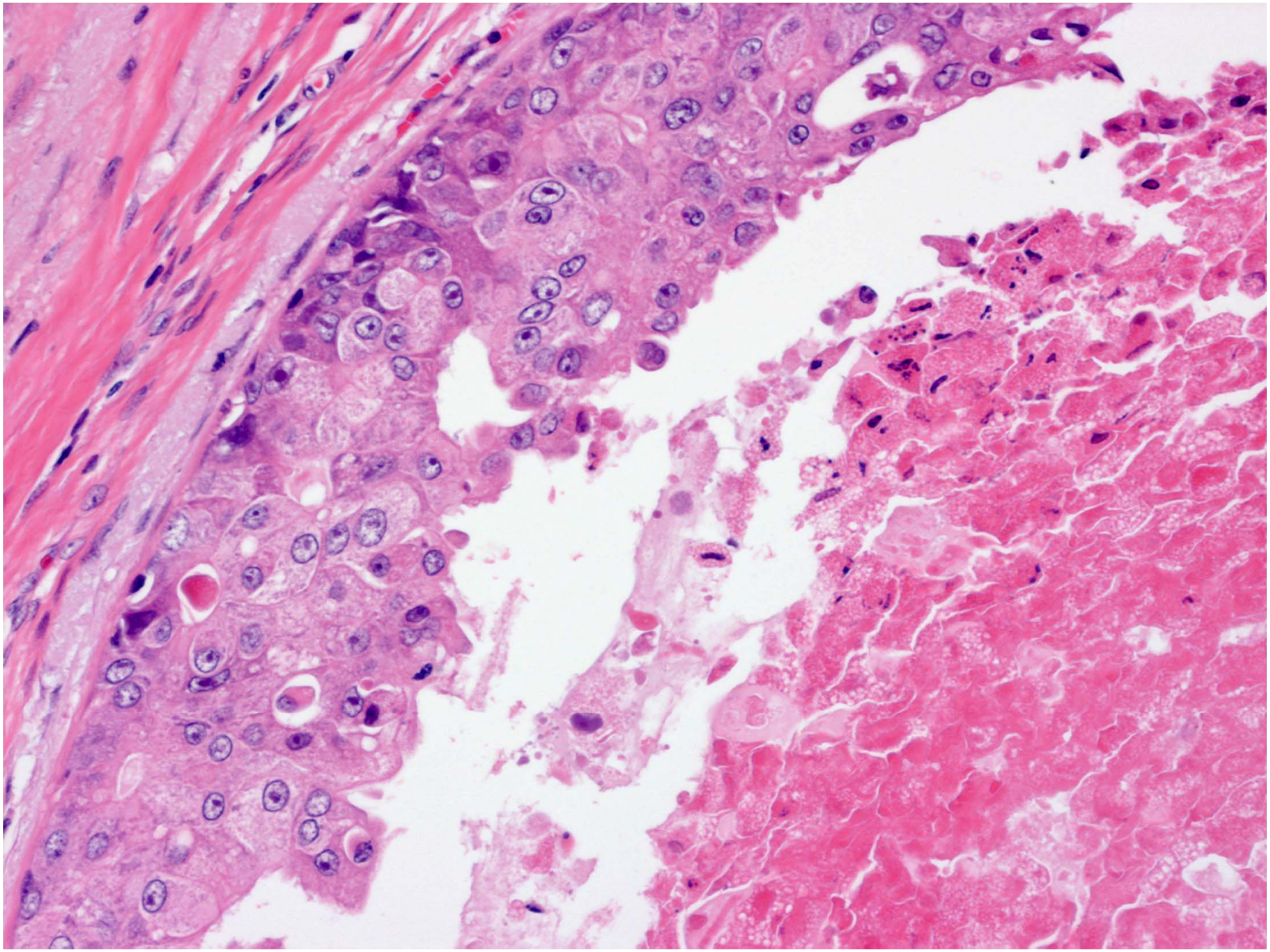

Apocrine DCIS involving adenosis

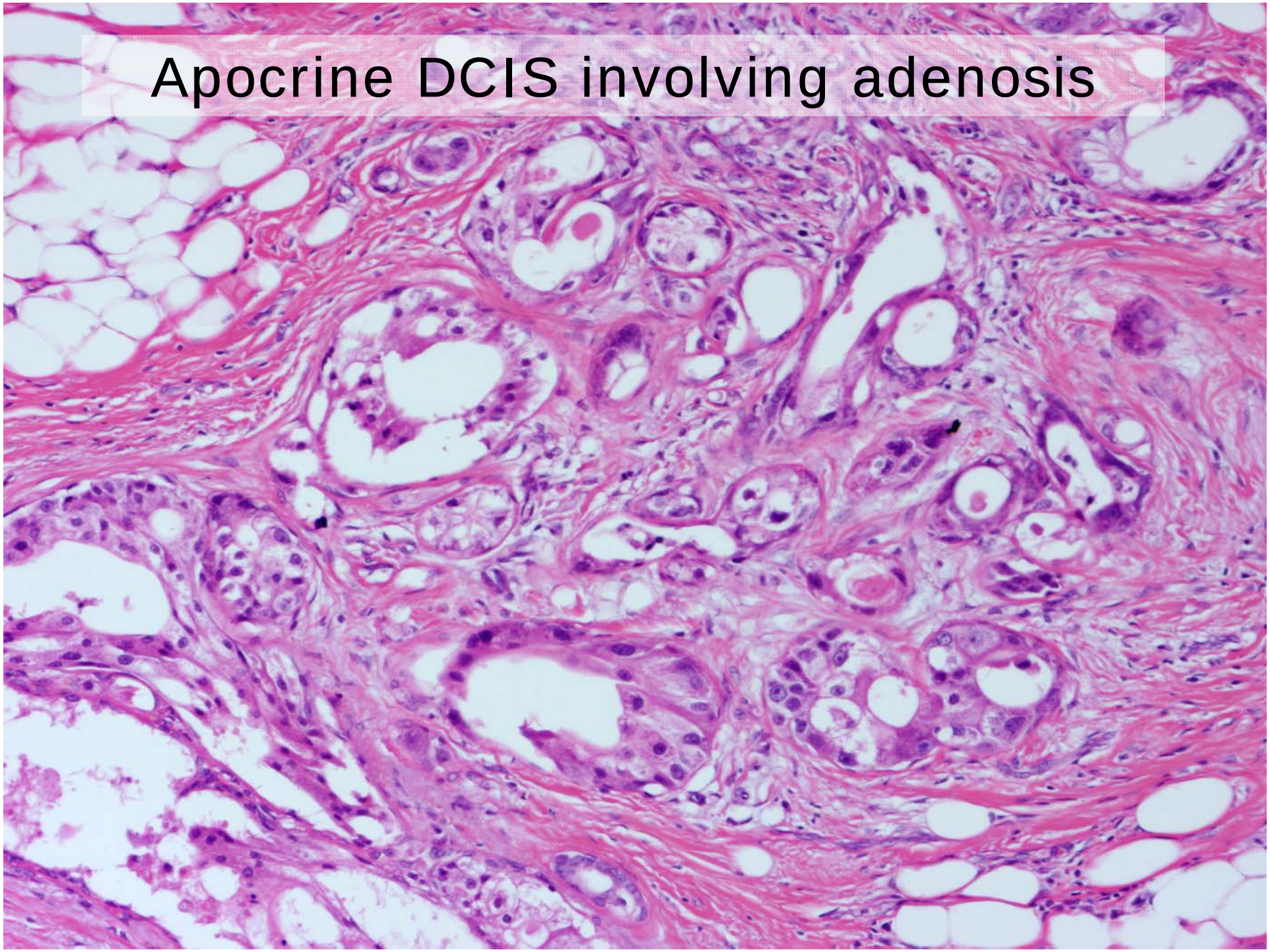

Apocrine DCIS involving adenosis

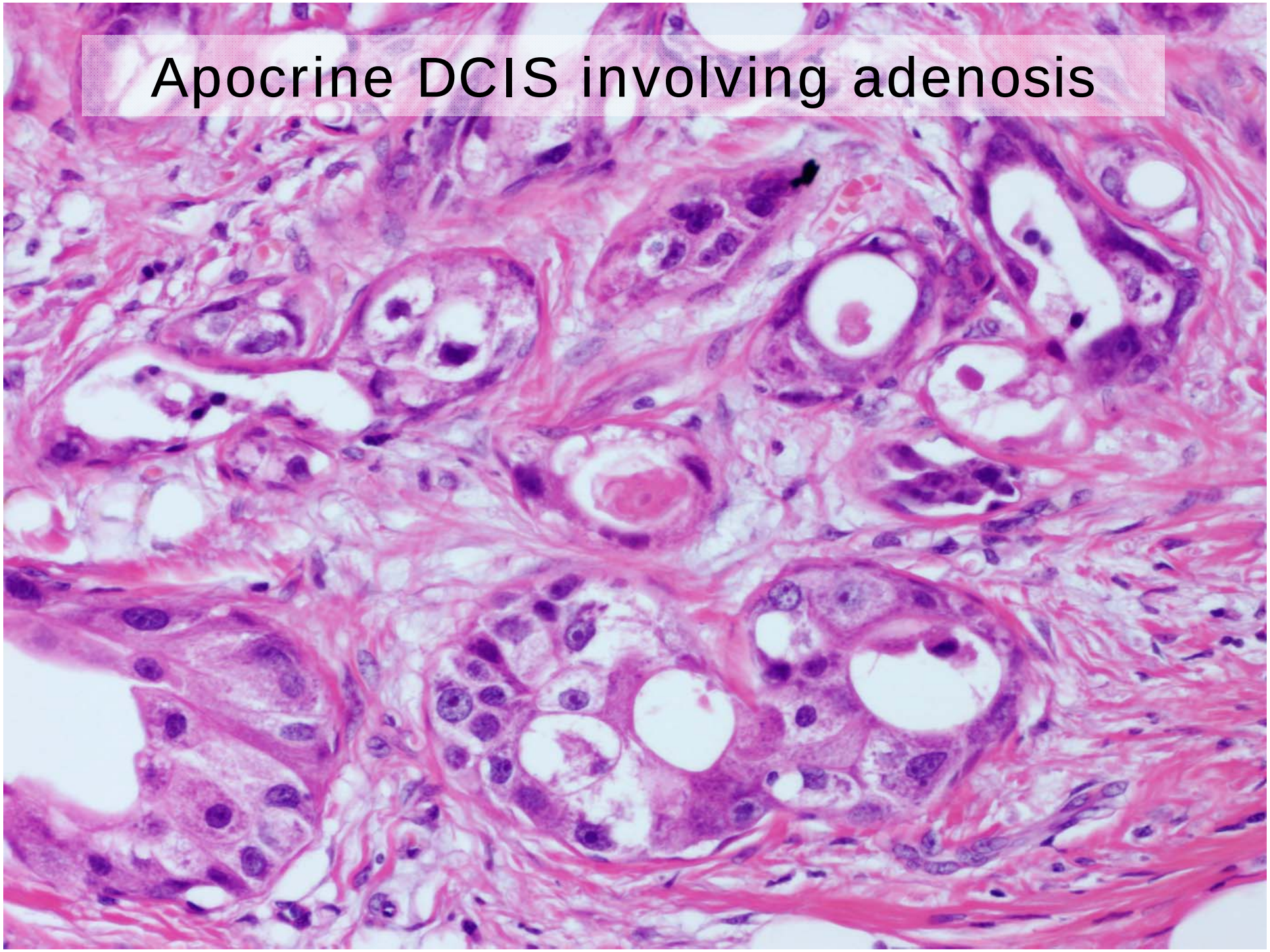

Apocrine DCIS involving adenosis

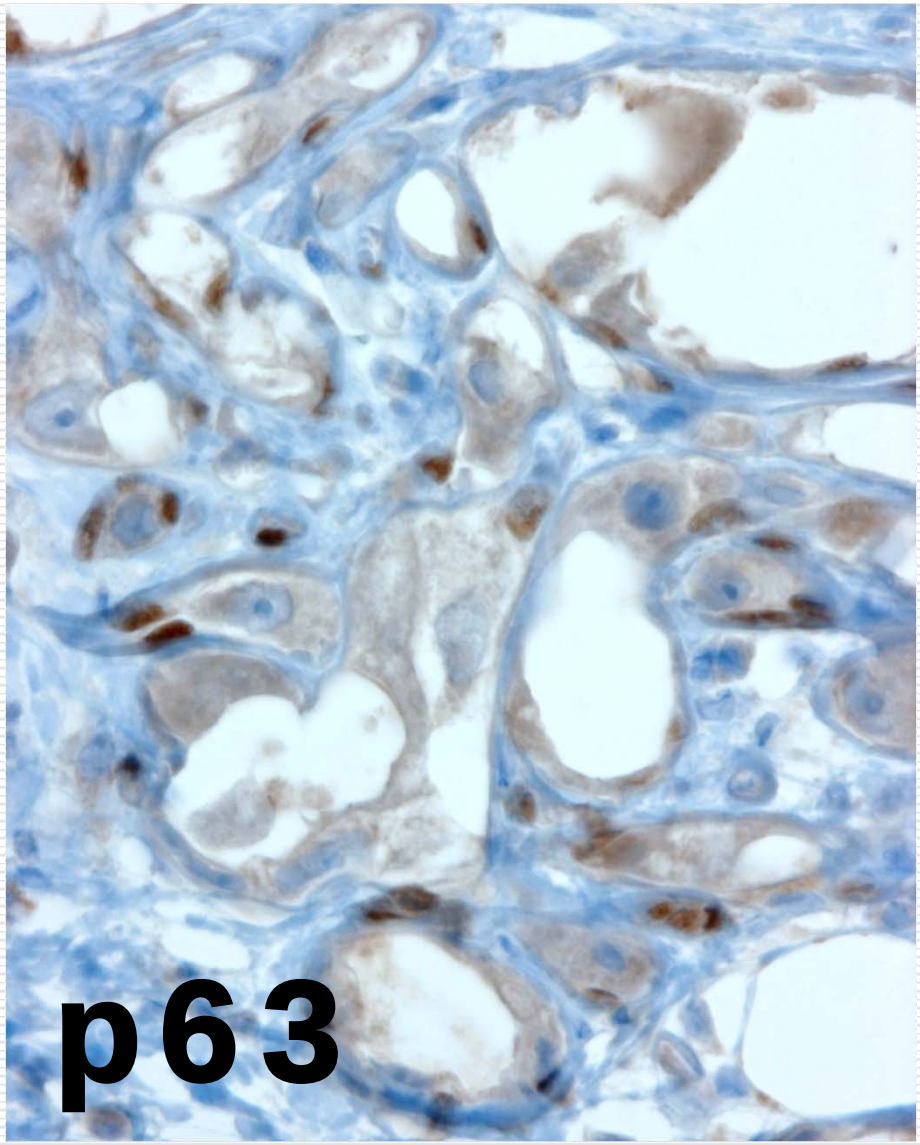

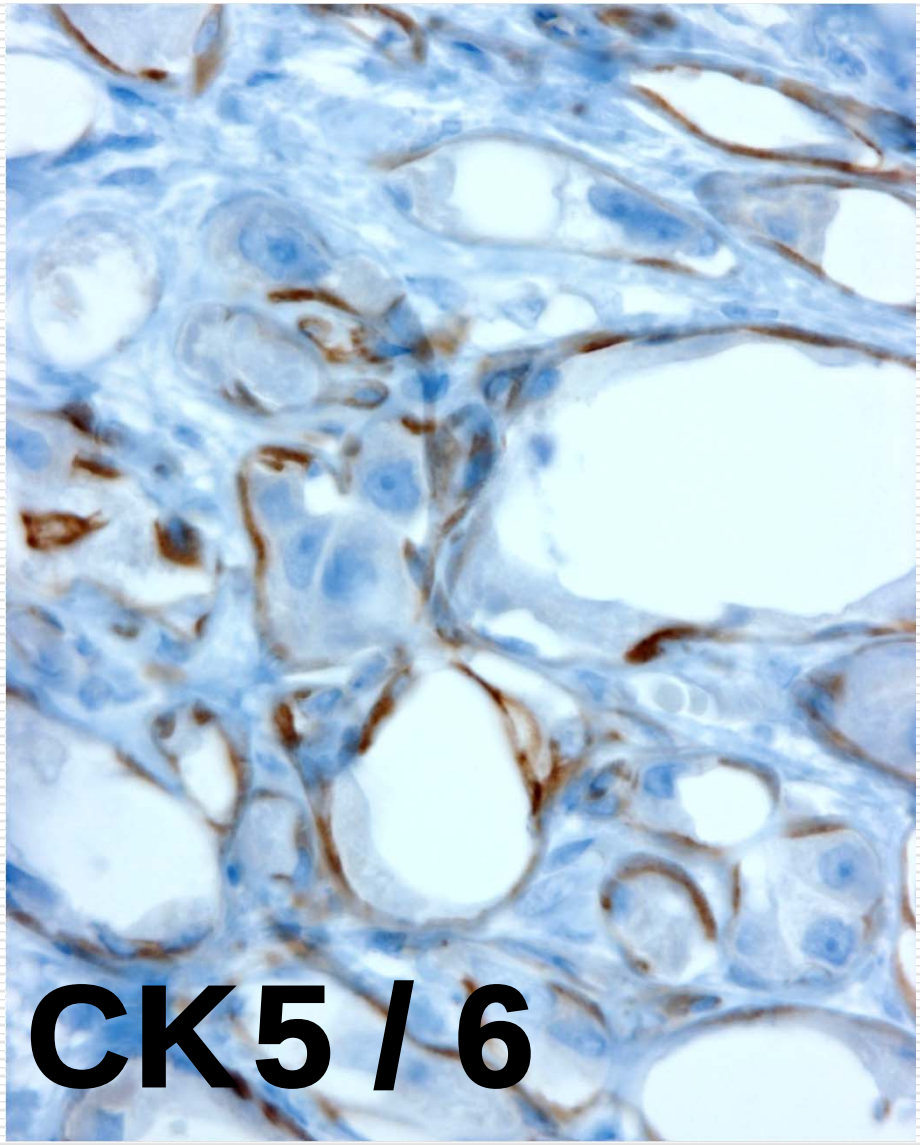

Papillary apocrine metaplasia

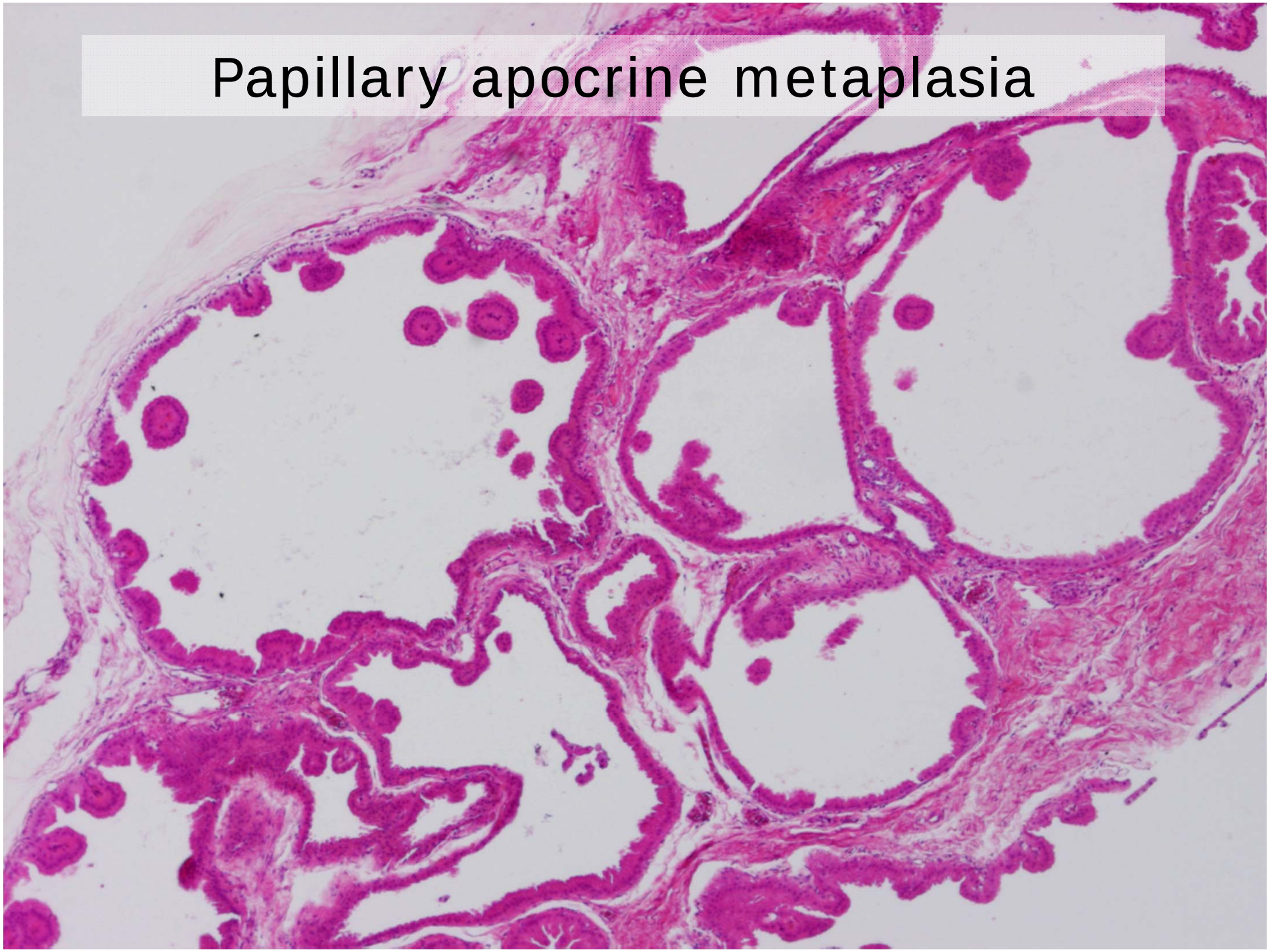

Papillary apocrine metaplasia

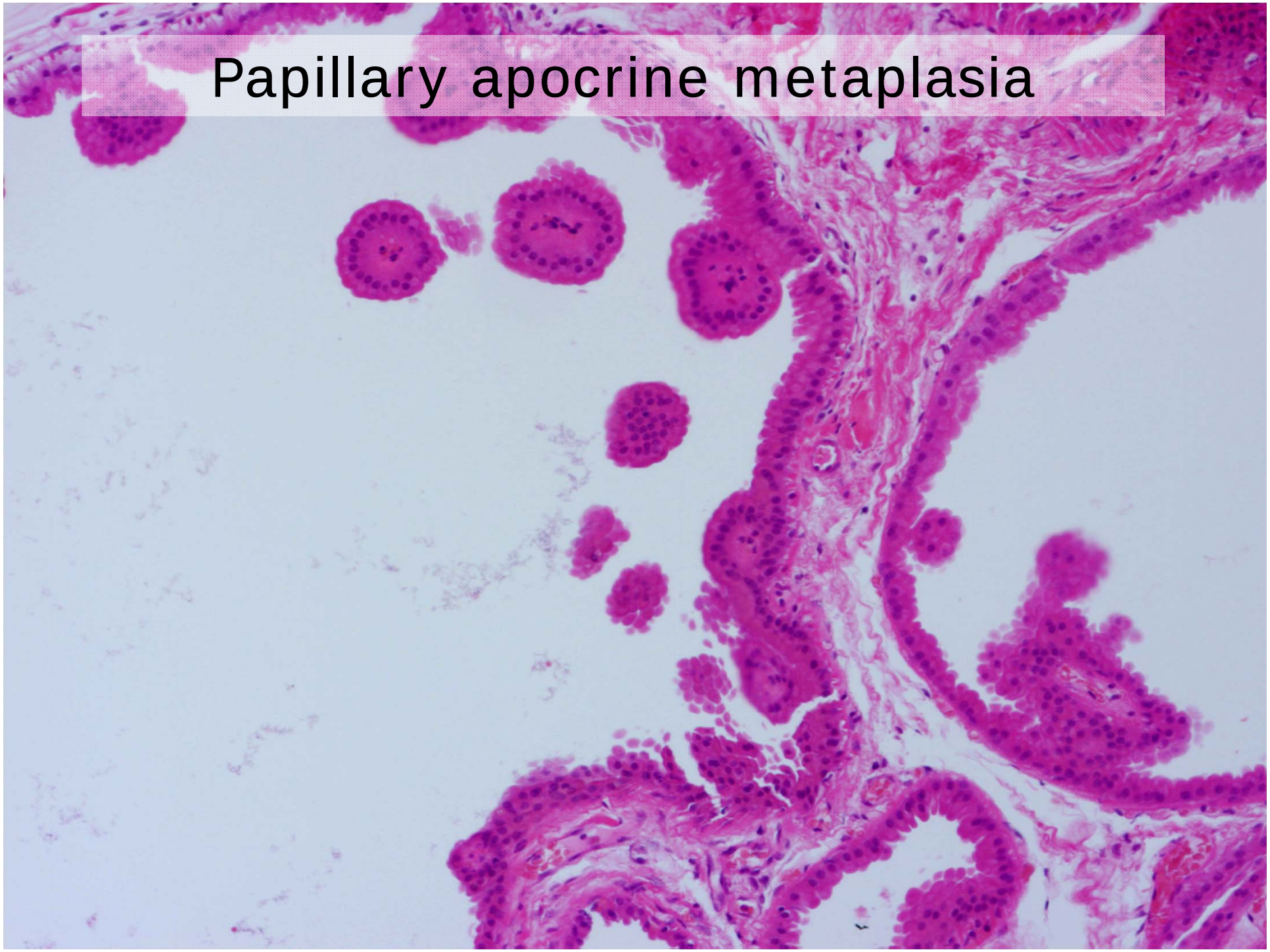

Papillary apocrine metaplasia

Apocrine LCIS

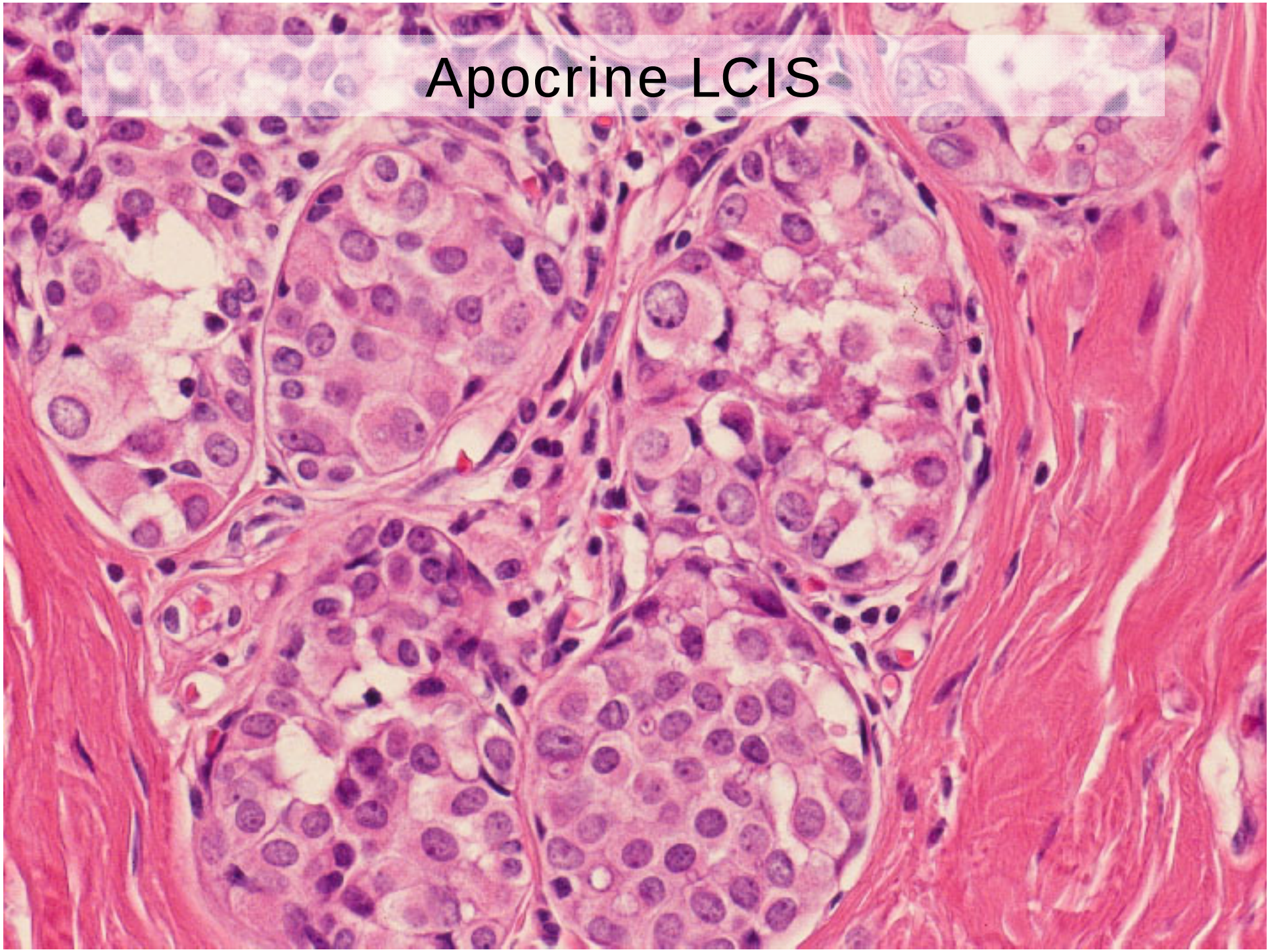

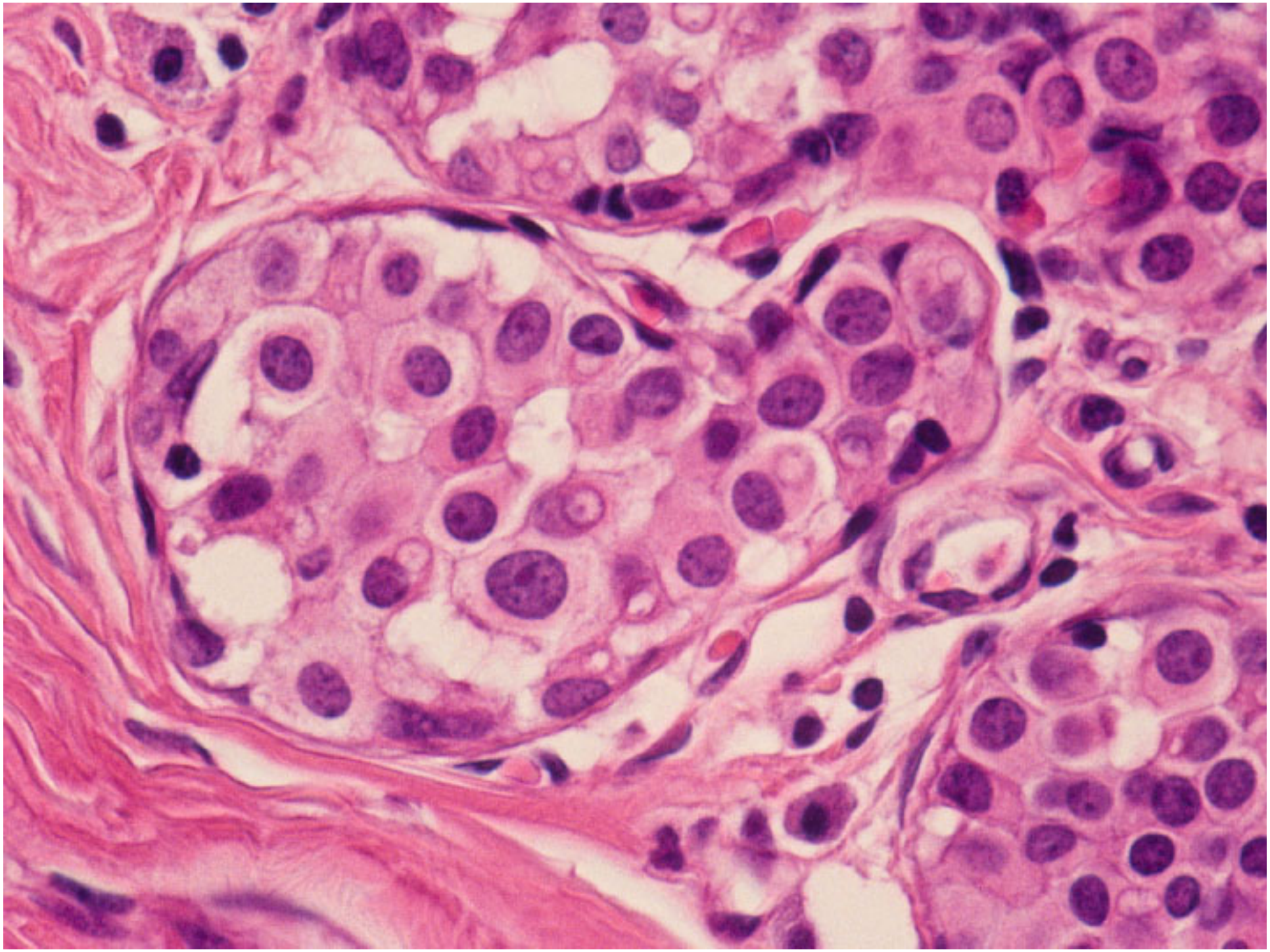

アポクリン癌
Apocrine carcinoma

- 免疫組織化学
  - GCDFP-15（prolactin-inducible protein）
    - 75%で陽性（乳全体では55%程度、アポクリン分化がない場合は25%）
  - Zinc-alpha-2-glycoproten
    - 35%で陽性
    - 生存率、無病生存期間と逆相関

アポクリン癌
Apocrine carcinoma

- 免疫組織化学
  - 98%ではER陰性、PR陰性（Tavassoli et al.）
  - 75%でER-β陽性
  - 94%ではAR陽性
  - 40～50%でHER2陽性
  - 88%でEGFR過剰発現（第7染色体コピー数増加）
  - 38～68%でp53陽性

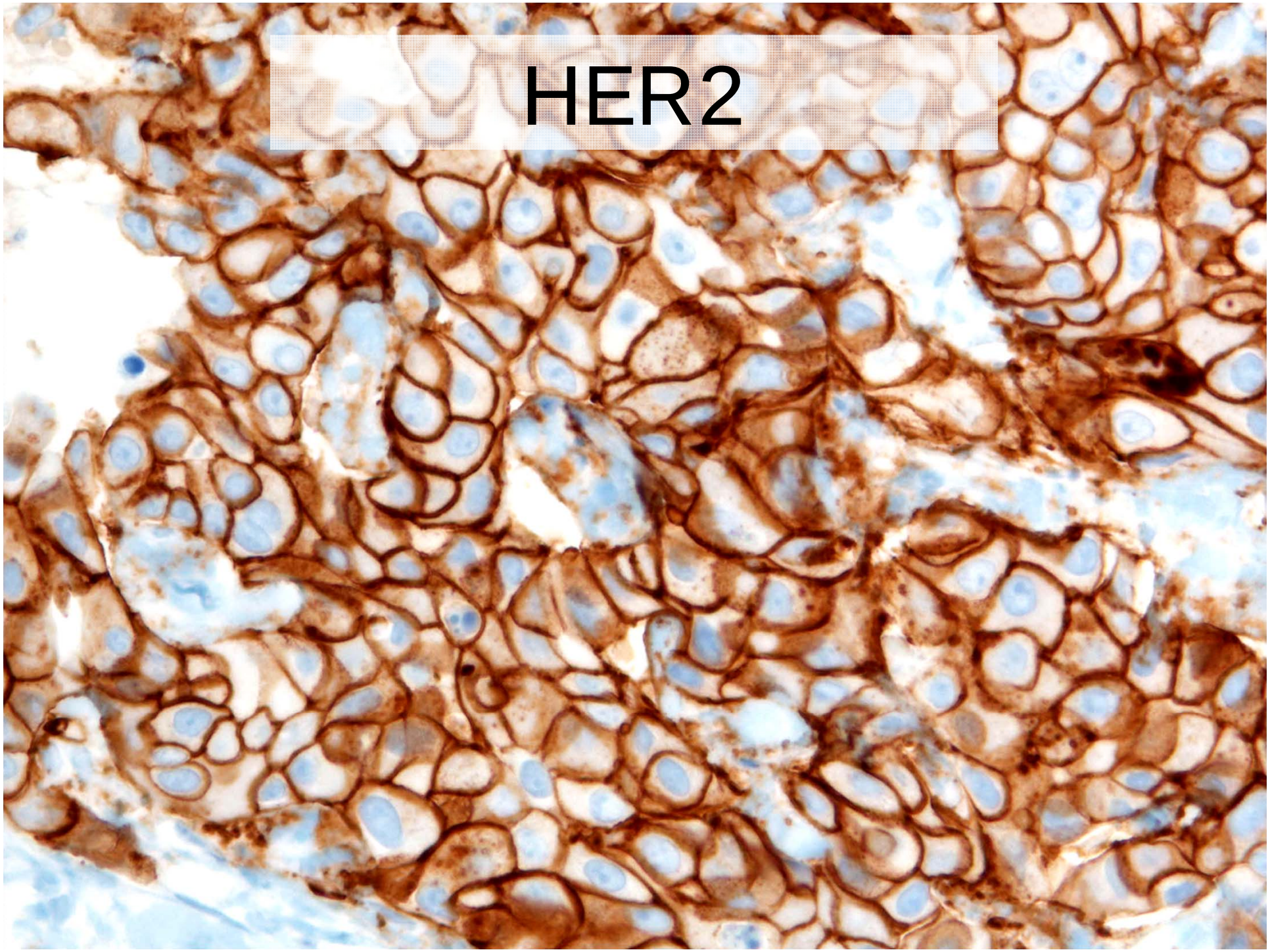
HER2

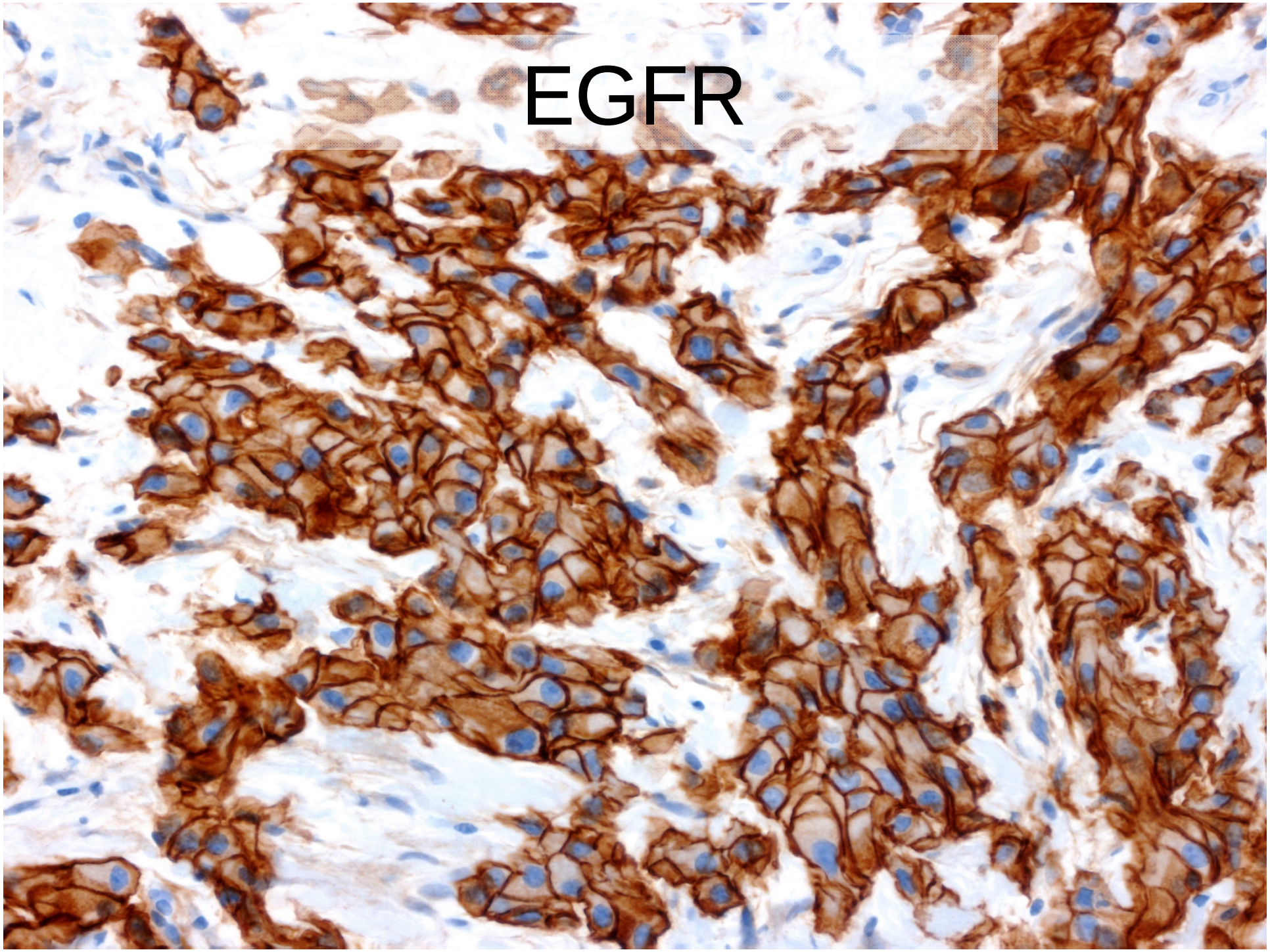
EGFR

アポクリン癌におけるEGFR and HER2発現の意義

- HER2過剰発現⇒54%
  - 遺伝子増幅：52%
- EGFR過剰発現（scores 1 to 3+）⇒62%
  - 純粋型：76% vs アポクリン様癌： 29% (P=0.006）
- HER2発現とEGFR発現は逆相関（P=0.006, r=-0.499）

Vranic S et al Mod Pathol;23:644-53.

アポクリン癌におけるEGFR and HER2発現の意義

- アポクリン癌（純粋型）はEGFR、HER2のいずれか一方を発現する
- アポクリン癌（純粋型）はHER2乳癌ないしトリプルネガティブ乳癌のいずれかである
（アポクリン様癌は主としてルミナルタイプ）

Vranic S et al Mod Pathol;23:644-53.

HER2乳癌は高頻度にアポクリン分化、基底細胞形質を示す

Molecular Class	Apocrine differentiation	Lymphoid Infiltrate	Necrosis
LUMA	4/113 (4%)	8/113 (7%)	0/113 (0%)
LUMB	2/34 (6%)	4/34 (12%)	4/34 (12%)
HER2	**7/8 (88%)**	**5/8 (63%)**	**3/8 (38%)**
TN	**9/32 (28%)**	**18/32 (56%)**	**8/32 (25%)**
LAHH	2/10 (25%)	0/10 (0%)	0/10 (0%)
LBHH	2/8 (25%)	0/8 (0%)	0/8 (0%)
P (HER2 vs TN)	**0.004**	**0.537**	**0.381**

LAHH: luminal A-HER2 Hybrid; LBHH: luminal B-HER2 hybrid

Bhargava R et al. Appl Immunohistochem Mol Morphol 2010; 18; 113-118

HER2乳癌は高頻度にアポクリン分化、基底細胞形質を示す

Molecular Class	CK5＋	EGFR 2＋/3＋
LUMA	0/107 (0%)	0/103 (0%)
LUMB	4/30 (13%)	1/29 (3%)
HER2	**5/8 (63%)**	**5/8 (63%)**
TN	**23/31 (71%)**	**6/30 (20%)**
LAHH	0/10 (0%)	0/10 (0%)
LBHH	0/8 (0%)	0/8 (0%)
P (HER2 vs TN)	**0.789**	**0.441**

LAHH: luminal A-HER2 Hybrid; LBHH: luminal B-HER2 hybrid

Bhargava R et al. Appl Immunohistochem Mol Morphol 2010; 18; 113-118

AR陽性のHER2乳癌は高頻度にアポクリン分化を示す

	AR＋	AR－
N	41	13
Apocrine morphology		
YES	**33 (80.5%)**	8 (61.5%)
NO	8 (19.5%)	5 (38.5%)
Histologic grade		
1/2	**17 (41.5%)**	1 (7.7%)
3	**24 (58.5%)**	**12 (92.3%)**

de Mottos Lima Lin et al. J Clin Pathol 2011: Oct 29 Ebub

ER陰性乳癌におけるARの発現の意義

Molecular Class	AR positive (%)		AR negative (%)		Total
LUMA	102	(96)	4	(4)	106
LUMB	24	(86)	4	(14)	28
HER2	**5**	**(63)**	**3**	**(37)**	**8**
TN	**3**	**(10)**	**27**	**(90)**	**30**
LAHH	9	(100)	0	(0)	9
LBHH	8	(100)	0	(0)	8
Total	151	(80)	38	(20)	189

LAHH: luminal A-HER2 Hybrid; LBHH: luminal B-HER2 hybrid

Niemeier LA et al. Mod Pathol 2010: 23: 205-212

ER陰性乳癌におけるARの発現の意義

	AR＋(=8)	AR－(n=30)	P-value
Average age	63 years	57 years	0.245
Mean tumor size (median)	1.5 cm (1.4 cm)	**2.2 cm (2.0 cm)**	0.151
Ductal phenotype	8/8 (100%)	30/30 (100%)	NS
Nottingham grade III	**3/8 (30%)**	**27/30 (90%)**	**0.005**
Necrosis	1/8 (13%)	**10/30 (33%)**	0.295
Apocrine differentiation	**6/8 (75%)**	**9/30 (30%)**	**0.039**
Lymph node metastasis	0/7 (0%); 1 NA	**8/26 (31%); 4 NA**	0.154

Niemeier LA et al. Mod Pathol 2010: 23: 205-212

ER陰性乳癌におけるARの発現の意義

- AR発現ER陰性乳癌
  ⇒“molecular apocrine”グループ

  ① HER2陽性乳癌（多くがアポクリン分化）
  ②トリプルネガティブ乳癌の一部

Niemeier LA et al. Mod Pathol 2010: 23: 205-212

“Molecular apocrine”

- 8-14% of IDCs
- Apocrine features (P=0.0002)
- Increased androgen signaling
- Frequent HER2 amplification
- ER(-) tumors outside the basal group

Farmer P et al. Oncogene 2005; 24: 4660-4671

Three groups based on steroid receptor activity

- Luminal (ER＋; AR＋)
- Basal (ER－; AR－)
- Molecular apocrine （ER－; AR＋）

Farmer P et al. Oncogene 2005; 24: 4660-4671

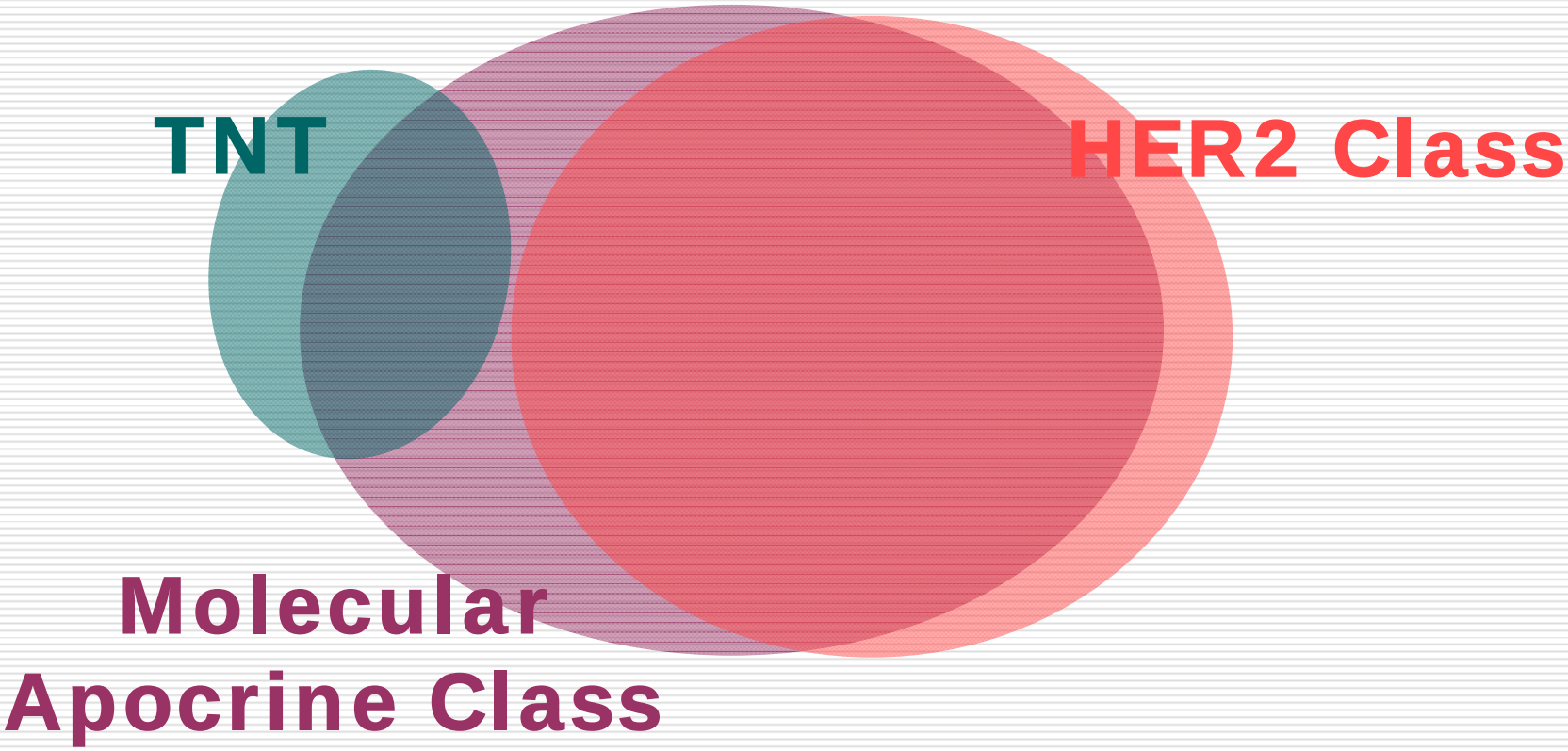
TNT
HER2 Class
Molecular
Apocrine Class

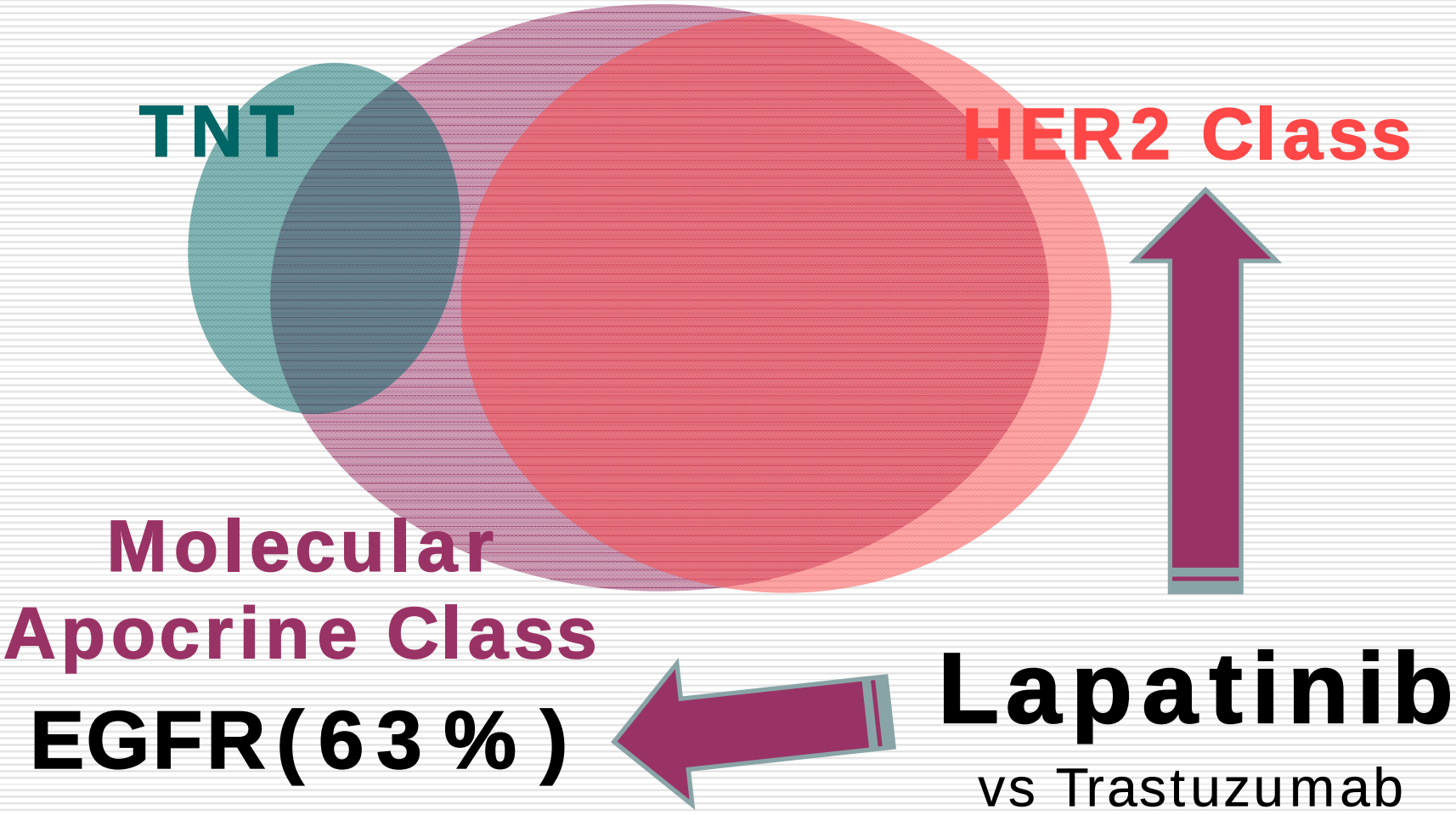
TNT
HER2 Class
Molecular
Apocrine Class
EGFR(63%)
Lapatinib
vs Trastuzumab

ご清聴
ありがとうございました

三上芳喜（三上芳喜）

京都大学病院病理診断部
mika@kuhp.kyoto-u.ac.jp